

REVIEW

Dissection of the aorta in Turner syndrome: two cases and review of 85 cases in the literature

M Carlson, M Silberbach

J Med Genet 2007;44:745–749. doi: 10.1136/jmg.2007.052019

Girls and women with Turner syndrome are at risk for catastrophic aortic dissection and rupture, but the clinical profile for those at risk is not well described. In addition to reporting two new cases, we performed an electronic search to identify all reported cases of aortic dissection associated with Turner syndrome. Particular attention was paid to the reporting of systemic hypertension (HTN) and congenital heart disease (CHD) which are known risk factors for aortic disease in the general population. In total, 85 cases of aortic dissection in TS were reported between 1961 and 2006. Dissection occurred at a young age, 30.7 (range 4–64) years, which is significantly earlier than its occurrence in the general female population (68 years). Of the cases for which HTN and CHD were explicitly assessed, 15% had HTN alone, 30% had CHD alone and 34% had both. Importantly, in 11% of the cases, neither HTN nor CHD were identified, suggesting that TS alone is an independent risk factor for aortic dissection; however, the cases where no risk factors were identified were very poorly documented. Dissection in women with TS undergoing assisted reproductive techniques (ART) frequently resulted in death. The literature on aortic dissection in TS is sparse and most cases are poorly documented, making it difficult to establish firm guidelines regarding monitoring and treatment. A TS aortic dissection registry has been established to better determine the natural history and risk factors (<http://www.tssus.org/readweb.asp?wid=3092>).

(1.4%).¹ Perhaps more importantly, the little information available is diffuse and disorganised, consisting of clinic-based studies,² unverified data obtained from questionnaires,³ and sporadic cases reports that describe only one or two cases of aortic dissection. A comprehensive review describing all of the reported cases of aortic dissection in TS has not been published. We describe two previously unreported cases of dissection occurring in young women with TS, review all of the published cases of aortic dissection occurring in TS, and announce the establishment of the International Turner Syndrome Aortic Dissection Registry. In this review, particular attention was paid to cases in which only the diagnosis of TS was present and other predisposing risk factors, such as congenital heart disease (CHD) or systemic hypertension (HTN), were expressly absent.

CASE REPORTS

Patient 1

An 18-year-old woman with TS (45,X) presented to an emergency department with full cardiac arrest. She had a 4-day history of chest pain. The patient died soon after presentation, and an autopsy revealed type A aortic dissection.

The patient had been treated with a tumour necrosis factor blocker (infliximab) for Crohn disease for 8 years. TS was diagnosed at the age of 14 years after an evaluation for short stature and delay of pubertal development. An echocardiogram performed at the time of the initial TS evaluation found a non-obstructive, functionally bicuspid aortic valve and trace aortic valve insufficiency. The patient had a mildly dilated ascending aorta of 28.5 mm (Z-score = 3.1). There was no evidence of coarctation. At 17 years of age, another echocardiogram reported ascending aorta diameters of 28 and 32 mm (Z-score = 2.2 to 3.8). Blood pressure was normal (102/60). Two days before death, the patient reported chest and upper back pain. Blood pressure was 108/84. The patient had abdominal pain with palpation and an audible abdominal bruit. Her paediatric cardiologist did not think there was a cardiac basis for her pain. She was told she had gastritis and started on antacid treatment.

Case 2

A 29-year-old woman with TS (45, X) presented to the emergency department with a 2-day history of shortness of breath and intermittent chest pain.

Abbreviations: ART, assisted reproductive techniques; BAV, bicuspid aortic valve; CHD, congenital heart disease, HTN, hypertension; TGF, transforming growth factor

See end of article for authors' affiliations

Correspondence to: M Silberbach, MD, Department of Pediatrics, CDRC-P, Oregon Health and Science University, 3181 SW Sam Jackson Park Rd, Portland, Oregon 97239-3098, USA; silberbm@ohsu.edu

Received 25 May 2007
Revised 14 August 2007
Accepted 16 August 2007
Published Online First
14 September 2007

Aortic dissection occurs in individuals with disorders of connective tissue, including those caused by fibrillin mutations (Marfan syndrome), collagen mutations (Ehlers–Danlos syndrome), transforming growth factor (TGF)- β receptor mutations (Loeys–Dietz syndrome), and in those in which a connective tissue disorder is postulated but not proven, such as bicuspid aortic valve syndrome and Turner syndrome (TS). In Marfan syndrome, guidelines for monitoring of aortic root dimension and indications for surgical intervention to prevent dissection are established, but for those with less common causes, treatment guidelines are lacking. In TS in particular, the medical community has been slow to recognise the evidence for the significant risk of catastrophic aortic dissection. This is partly because aortic dissection is relatively rare in TS

Shortly after presentation, she became unresponsive, apnoeic and pulseless. Cardiopulmonary resuscitation was started, but the patient died. Before the arrest, pallor and rales had been noted and thrombolytic treatment started for presumed pulmonary embolus. Type A aortic dissection was found at autopsy. In addition to TS, the patient had a bicuspid aortic valve, hypertension (treated with atenolol), hypothyroidism, and a history of bipolar disorder that was treated with lithium and an antidepressant.

The patient’s most recent echocardiogram 15 months prior to the dissection showed a mildly thickened aortic valve without stenosis or insufficiency, mild mitral valve thickening and normal systolic function. The aortic root diameter measured 22 mm ($z = -0.5$). Despite beta-blocker treatment, the most recent blood pressure measurements showed systemic hypertension (142/82).

LITERATURE REVIEW

We performed an electronic search from 1961 to 2006 designed to capture all reported cases of aortic dissection in girls and women with TS (key words: Turner syndrome, aortic dissection, aortic dilatation). Cases were excluded if aortic dissection in Turner syndrome was not explicit. However, cases were still included in the review even if the method of diagnosing heart disease or measuring blood pressure were not precisely stated. In total, 23 articles, 5 short commentaries, 4 letters to the editor and 8 abstracts were ultimately included in this report. Cases were cross-referenced in order to avoid duplication of cases. Age at dissection, location of dissection, mention of known risk factors (ie CHD and/or HTN), treatment and outcome were recorded.

RESULTS

In total, 88 cases were reported between 1961–2006. Of these, 85 cases were included in this review; 3 cases were excluded because they lacked identifying information. The mean age at time of dissection was 30.7 (range 4–64) years. Over half the patients were aged <30 years. A karyotype was reported in 58% (49/85). A 45X karyotype was present in 80% (39/49) of the cases where karyotype was reported. In 10 cases, various forms of mosaicism were described: 45X/46XX (1 patient), 45X/46XY (3), 45X/46X,r(X) (4), 45X/46X+mar4 (1) and not specified (1). The location of the aortic dissection was provided in 71 of the 85 cases. Over half (55%; 47/85) of the dissections occurred in

the proximal aorta and 23% (20/85) in the distal aorta. In three cases, both the ascending and descending aortas were involved. CHD was reported in 69% (51/74) cases that were evaluated for CHD. Of these 51 cases, 47% (24/51) had reported coarctation of the aorta, 27% (14/51) bicuspid aortic valve (BAV) and 18% (9/51) both BAV and a coarctation. Of the 65 cases in which blood pressure and CHD were both explicitly assessed (fig 1), 54% (35/65) had hypertension, although in most of the cases the blood pressure values were not reported. In addition, in this group, for which both risk factors were assessed, 75% (49/65) had associated CHD. The online supplementary tables (available at <http://jmg.bmj.com/supplemental>) report the cases in which CHD occurred in isolation (Table S1, references 4–20), in which hypertension was the only risk factor described (Table S2, references 21–24), and in which both CHD and hypertension were present (Table S3, references 25–39).

Assisted reproductive technology (ART) resulted in pregnancy complicated by aortic dissection in six instances.^{40–44} In a seventh case death occurred 1 year after ART.⁴⁰ Maternal death was reported in 86% (6/7) of these cases.

No risk factors were reported in 21% (18/85) overall (table 1). Importantly, most case reports that listed no risk factors did not explicitly exclude them. However, in 11% (7/65), the presence (or absence) of CHD and HTN was specifically investigated and not identified (table 1, fig 1). The age range of these seven women was between 20 and 53 (mean 36) years. In one case, aortic dissection occurred during the third trimester in a pregnant women who had ART.⁴⁰ Four of six cases reported a proximal aortic dissection and in one case the dissection was both proximal and distal. Although all seven cases excluded HTN and CHD, only two cases reported the actual blood pressure values, and the method used to exclude CHD was described in only three cases.

The symptoms most commonly reported before dissection were chest pain, diaphoresis and tachycardia. In the majority of cases, surgical and/or medical treatments were tried. In all 22 instances in which the pathology of the aorta was reported, it was found to be cystic medial necrosis. In 83 of the cases an outcome was reported, with death occurring in 48/83 cases (58%).

DISCUSSION

In this review, 85 cases of dissection of the aorta were identified in women with TS. These data demonstrate that in most cases a known risk factor for dissection is present, either systemic hypertension, a predisposing cardiac malformation or both. Of significant concern are the reports of aortic dissection occurring in seven women during ART. In one study of pregnancy in women with coarctation, the only death was due to aortic dissection in a woman with TS.⁴² Although there are no data regarding how commonly ART is undertaken by TS women, the fact that most women (86%) in our review died suggests that pregnancy is a major risk factor in TS. Dissection of the aorta occurs in TS at a remarkably young age (mean 31 years). In contrast, the International Registry of Acute Aortic Dissection found that the mean age of dissection in non-TS women is 68 years.⁴⁵ Furthermore, aortic dissection is predominantly a male disease (male:female ratio 3.2:1, age-adjusted mortality rate).⁴⁶ The reasons that aortic dissection occurs in this unique group of young women deserves further attention.

Bicuspid aortic valve, aortic coarctation and systemic hypertension are established risk factors for aortic dissection in the general population⁴⁷ and they often occur in TS. Approximately 25–30% of women with TS have a cardiovascular malformation and of those affected, most have aortic disease.^{48–49} Systemic hypertension has been reported to occur in 50% of women with TS.⁴⁹ Thus, in TS there appears to be

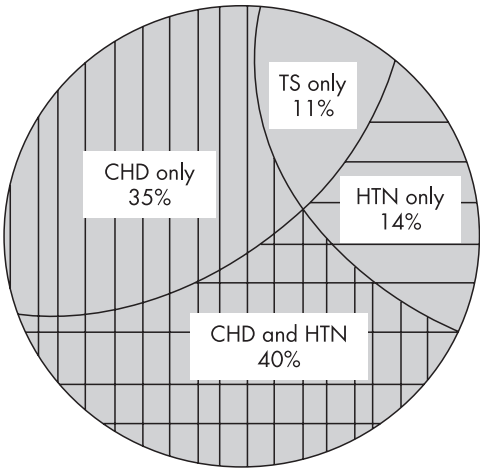


Figure 1 Venn diagram of 65 people with TS who had aortic dissection where signs of congenital heart disease (CHD) or systemic hypertension (HTN) were explicitly considered.

Table 1 Patients with no hypertension or congenital heart disease

Patient no	Age, years	Heart disease	Hypertension	Karyotype	Outcome	Pathology	Location of dissection	Other information	CHD exclusion criteria	Reference
1	20	No	No	45,X	Deceased	CMN	Proximal		NR	Rubin ⁵⁵
2	27	No	No	NR	Alive	NR	Very distal	Abdominal aorta	Echo, angiography, MRI	Bartlema ⁵⁶
3	30	No	No	45X/46X + ring	Deceased	CMN	Proximal		Autopsy	Price ⁵⁷
4	39	No	No	45,X	Deceased	NR	Proximal and distal		Autopsy	Price ⁵⁷
5	51	No	No	45,X/46 X, r(X)	Alive	NR	Proximal		NR	Gravholt ¹
6	53	No	No	45,X	Deceased	NR	Proximal		NR	Gravholt ¹
7	NR	No	No	NR	Deceased	NR	NR	Dissection during third trimester of pregnancy	NR	Nagel ⁴⁰
8	9.5	NR	No	45,X	Alive	NR	Site of surgical repair?		NR	Sybert ²
9	10	No	NR	NR	Deceased	NR	Proximal		NR	Hata ⁵⁸
10	18	NR	NR	45 X/46XY	Deceased	CMN	Proximal		NR	Gravholt ¹
11	28	NR	No	45,X	Deceased	NR	Distal		NR	Gravholt ¹
12	29	No	NR	45,X/46X,r(X)	Deceased	NR	NR		Price ⁵⁹	
13	30	NR	NR	NR	Alive	NR	Proximal	Surgical repair	NR	Hirose ⁶⁰
14	34	NR	NR	NR	NR	NR	NR	Dissection of aortic aneurysm	NR	Chlumsky ⁶¹
15	38	NR	NR	45,X	Alive	NR	Proximal	Surgical repair	NR	Meunier ⁶²
16		NR	NR	NR	Alive	NR	Distal		NR	Clement ⁶³
17	39	No	NR	45,X	Deceased	NR	NR		NR	Price ⁵⁹
18	49	No	NR	NR	Deceased	NR	NR		NR	Hata ⁵⁸
19	61	NR	No	45,X	Deceased	NR	NR		NR	Gravholt ¹

AI, aortic insufficiency; AS, aortic stenosis; BAV, bicuspid aortic valve; BE, subacute bacterial endocarditis; CMN, cystic medial necrosis; LCA, left coronary artery; NR, not reported; SCHD, coronary heart disease.

a confluence of established risk factors leading to aortic dissection. In support of this theory, we found that 89% of cases of aortic dissection had at least one established risk factor. On the other hand, we and others³ have found no identifiable risk factor in approximately 11% of cases. This could be because the known associations were not adequately assessed. Indeed, the cases we reviewed that carried the claim of no risk factors were, for the most part, very poorly documented. However, others have suggested that TS involves a primary disorder of the composition of the aortic wall that creates vulnerability by lowering the threshold for dilation, dissection and rupture. The data in table 1 showing that some patients had neither of the established risk factors suggest that TS alone may be predisposing to aortic dissection. Histological evidence of cystic medial necrosis in aortic tissue taken from patients with bicuspid aortic valve, Marfan syndrome and TS suggests a common aetiology despite genetically diverse backgrounds. In this regard, Ostberg *et al*⁵⁰ recently documented intimal-medial thickening and vessel dilation diffusely in the vasculature, including the aorta in women with TS, even in the absence of CHD. Interestingly, similar pathological findings are typically present in other aortopathies, including Marfan syndrome. The presence of vessel wall thickening in these diseases is evidence against the conventional view that increased wall stress produced by high blood pressure, jets from stenotic aortic valves, or abnormal proteins of the aortic tissue produce thinning of the vessel wall, which leads to dilation and eventual aortic rupture. Other observations⁵¹ suggest that a disorder of growth-factor signal transduction ultimately weakens the aortic wall. These studies report a variety of aortic diseases in which there is a constellation of findings, including vessel wall thickening, upregulation of TGF-β signalling and proliferation of matrix proteins. In TS the observation of aortic

wall thickening suggests that it may also be a disorder associated with upregulation of TGF-β signalling. Knowledge of the natural history and clinical findings of Marfan syndrome has been used to make judgments regarding proper monitoring and treatment of TS individuals with aortic enlargement. However, it is clear from this review that very little is known about the prodrome of aortic dissection in this population. For example, it is completely unknown whether aortic dissection is preceded by progressive dilation of the aortic root as it is in Marfan syndrome. Indeed, in both of the new cases presented in this report, the most recent aortic Z-score determined by echocardiography was <4, a value that most cardiologists would not consider to be at risk for imminent dissection. We conclude from our review that there is a profound lack of a reliable medical profile for those with TS who have dissected. Accordingly, it is appropriate that the position of the American Academy of Pediatrics on the monitoring and management of aortic disease in TS is open-ended, recommending that medical monitoring should be determined by the primary cardiologist or care provider.⁵² The Turner Syndrome NIH Consensus Study Group recently published more focused guidelines,⁵³ but also with little evidence to support their recommendations. These guidelines recommend a baseline echocardiogram to assess for congenital heart disease and frequent blood pressure screening. For those who have no cardiovascular disease or hypertension, the recommendations include reassessment of the cardiovascular system with a cardiac MRI when sedation is not necessary and repeating either an echocardiogram or MRI every 5–10 years. However, it is unclear if surveillance studies would be able to detect progressive aortic dilatation or imminent dissection. To gain a better understanding of the natural history of aortic dissection in women with TS, we have established an

International Turner Syndrome Aortic Dissection Registry (ITSADR, <http://www.tssus.org/readweb.asp?wid=3092>).⁵⁴ Its goal is to identify all girls and women with TS and aortic dissection, to profile their risk factors and to more precisely define the appearance and progression of aortic disease leading to dissection.

All doctors who care for women with TS should be aware of their risk for aortic dissection. The apparent risk during pregnancy for those receiving ART must be recognised and early education of TS women contemplating pregnancy is mandatory. We found that in many of the reported cases and in the two cases presented here, the symptoms developed insidiously over the course of hours to days. A preliminary review of the data of the ITSADR suggests that the signs and symptoms that may herald an aortic dissection include apparently minor complaints such as abdominal pain, "heart-burn", back or shoulder pain, or a change in phonation (due to traction on the recurrent laryngeal nerve). Symptoms that persist should always be taken seriously and warrant complete investigation including transesophageal echocardiography, chest CT or cardiac MR.

ACKNOWLEDGEMENTS

We wish to thank Dr R Shaughnessy for her careful review of the manuscript and helpful comments, K Gaeta for preparation of the tables and the Turner Syndrome Society of the United States for their support of the International Turner Syndrome Aortic Dissection Registry.



Supplementary material is available on the JMG website at <http://jmg.bmj.com/supplemental>

Authors' affiliations

M Carlson, M Silberbach, Division of Pediatric Cardiology, Doernbecher Children's Hospital, Oregon Health & Science University, Oregon, USA

Competing interests: none declared.

REFERENCES

- Gravholt CH, Landin-Wilhelmsen K, Stochholm K, Hjerrild BE, Ledet T, Djurhuus CB, Sylven L, Baandrup U, Kristensen BO, Christiansen JS. Clinical and epidemiological description of aortic dissection in Turner's syndrome. *Cardiol Young* 2006;**16**:430–6.
- Sybert VP. Cardiovascular malformations and complications in Turner syndrome. *Pediatrics* 1998;**101**:E11.
- Lin AE, Lippe B, Rosenfeld RG. Further delineation of aortic dilation, dissection and rupture in patients with Turner syndrome. *Pediatrics* 1998;**102**:e12.
- Asch AJ. Turner's syndrome occurring with Horner's syndrome. Seen with coarctation of the aorta and aortic aneurysm. *Am J Dis Child* 1979;**133**:827–30.
- Buheitel G, Singer H, Hofbeck M. [Aortic aneurysms in Ullrich-Turner syndrome]. *Klinische Padiatrie* 1996;**208**:42–5.
- Guerin FGD, de Saint-Maur P, Akoun J, Josso N. Dissection aortique et syndrome de Turner. *Coeur* 1974;**5**:771–5.
- Imamura M, Aoki H, Eya K, Murakami T, Yasuda K. Balloon angioplasty before Wheat's operation in a patient with Turner's syndrome. *Cardiovasc Surg* 1995;**3**:70–2.
- Kusaba E, Imada T, Iwakuma A, Nonaka K. [Aortic aneurysm complicated with coarctation of the aorta and Turner syndrome]. *Kyobu Geka* 1995;**48**:1115–17.
- Vesin S, Chudanova V. [Aortic aneurysm in Turner's syndrome]. *Cesk Radiol* 1989;**43**:226–9.
- Allemann J, Muller G, Legat M. [Rare variant of a Turner-Ullrich syndrome]. *Schweiz Med Wochenschr* 1982;**112**:1249–55.
- Ohuchi H, Takasugi H, Ohashi H, Okada Y, Yamada O, Ono Y, Yagihara T, Echigo S. Stratification of pediatric heart failure on the basis of neurohormonal and cardiac autonomic nervous activities in patients with congenital heart disease. *Circulation* 2003;**108**:2368–76.
- Edwards WD, Leaf DS, Edwards JE. Dissecting aortic aneurysm associated with congenital bicuspid aortic valve. *Circulation* 1978;**57**:1022–5.
- Goldberg SM, Pizzarello RA, Goldman MA, Padmanabhan VT. Aortic dilatation resulting in chronic aortic regurgitation and complicated by aortic dissection in a patient with Turner's syndrome. *Clin Cardiol* 1984;**7**:233–5.
- Shiroma K, Ebine K, Tamura S, Yokomuro M, Suzuki H, Takanashi Y. A case of Turner's syndrome associated with partial anomalous pulmonary venous return complicated by dissecting aortic aneurysm and aortic regurgitation. *J Cardiovasc Surg* 1997;**38**:257–9.
- Kosich ND, Opitz JM. Ullrich-Turner syndrome associated with cystic medial necrosis of the aorta and great vessels: case report and review of the literature. *Am J Med* 1965;**38**:943–50.
- Apostolopoulos T, Kyriakidis M, Toutouzas P. Endarteritis of the aortic arch in Turner's syndrome with cystic degeneration of the aorta. *Int J Cardiol* 1992;**35**:417–19.
- Slater DN, Grundman MJ, Mitchell L. Turner's syndrome associated with bicuspid aortic stenosis and dissecting aortic aneurysm. *Postgrad Med J* 1982;**58**:436–8.
- Martin MM, Beekman RH, Rocchini AP, Crowley DC, Rosenthal A. Aortic aneurysms after subclavian angioplasty repair of coarctation of the aorta. *Am J Cardiol* 1988;**61**:951–3.
- Ravelo HR, Stephenson LW, Friedman S, Chatten J, Rashkind WJ, Vidas M, Edmunds LH Jr. Coarctation resection in children with Turner's syndrome: a note of caution. *J Thorac Cardiovasc Surg* 1980;**80**:427–30.
- Oohara K, Yamazaki T, Sakaguchi K, Nakayama M, Kobayashi A. Acute aortic dissection, aortic insufficiency and a single coronary artery in a patient with Turner's syndrome. *J Cardiovasc Surg (Torino)* 1995;**36**:273–5.
- Lippe BM, Kogut MD. Aortic rupture in gonadal dysgenesis. *J Pediatr* 1972;**80**:895–6.
- Kido G, Miyagi A, Shibuya T, Miyagami M, Tsubokawa T, Sawada T. [Turner's syndrome with pituitary hyperplasia: a case report]. *No Shinkei Geka* 1994;**22**:333–8.
- Akimoto N, Shimizu T, Ishikawa M, Ishimaru S, Furukawa K. The surgical treatment of aortic dissection in a patient with Turner's syndrome: report of a case. *Surg Today* 1994;**24**:929–32.
- Salgado CR. [Turner's syndrome. Report of a case associated with dissecting aneurysm of the aorta. Review of the literature]. *Rev Fac Cienc Med Cordoba* 1961;**19**:193–204.
- Ota Y, Tsunemoto M, Shimada M, Ishizawa A, Koike K, Kobayashi J. [Aortic dissection associated with Turner's syndrome]. *Kyobu Geka* 1992;**45**:411–14.
- Strader WJ 3rd, Wachtel HL, Lundberg GD Jr. Hypertension and aortic rupture in gonadal dysgenesis. *J Pediatr* 1971;**79**:473–5.
- Fejic Z, van Oort A. Fatal dissection of the descending aorta after implantation of a stent in a 19-year-old female with Turner's syndrome. *Cardiol Young* 2005;**15**:529–31.
- Youker JE, Roe BB. Aneurysm of the aortic sinuses and ascending aorta in Turner's syndrome. *Am J Cardiol* 1969;**23**:89–93.
- Cecchi F, Samoun M, Santoro G, Calamai G. [Chronic dissecting aortic aneurysm and Turner's syndrome. Apropos of a case]. *Arch Mal Coeur Vaiss* 1992;**85**:1043–6.
- Bordeleau L, Cwinn A, Turek M, Barron-Klauninger K, Victor G. Aortic dissection and Turner's syndrome: case report and review of the literature. *J Emerg Med* 1998;**16**:593–6.
- Subramaniam PN. Turner's syndrome and cardiovascular anomalies: a case report and review of the literature. *Am J Med Sci* 1989;**297**:260–2.
- Anabtawi IN, Ellison RG, Yeh TJ, Hall DP. Dissecting aneurysm of aorta associated with Turner's syndrome. *J Thorac Cardiovasc Surg* 1964;**47**:750–4.
- Lie JT. Aortic dissection in Turner's syndrome. *Am Heart J* 1982;**103**:1077–80.
- Pollak H, Veit F, Enekel W. [Presumed "successful" fibrinolysis in unrecognized acute aortic dissection]. *Dtsch Med Wochenschr* 1992;**117**:368–71.
- Badmanaban B, Mole D, Sarsam MA. Descending aortic dissection post coarctation repair in a patient with Turner's syndrome. *J Card Surg* 2003;**18**:153–4.
- Gopal AS, Arora NS, Vardanian S, Messineo FC. Utility of transesophageal echocardiography for the characterization of cardiovascular anomalies associated with Turner's syndrome. *J Am Soc Echocardiogr* 2001;**14**:60–2.
- Hochberg Z. Sudden death in Turner's syndrome. *Harefu* 1995;**129**:285–8.
- Jeresaty RM, Basu SK, Franco J. Dissecting aneurysm of the aorta in Turner's syndrome. *JAMA* 1972;**222**:574–6.
- Miller JM HE, Puga UC, Torres GS. Syndrome de Turner y aneurisma disecante de la aorta. *Arch Inst Cardiol Mex* 1974;**44**:771–5.
- Nagel TC, Tesch LG. ART and high risk patients! *Fertil Steril* 1997;**68**:748–9.
- Landin-Wilhelmsen K, Bryman I, Hanson C, Hanson L. Spontaneous pregnancies in a Turner syndrome woman with Y-chromosome mosaicism. *J Assist Reprod Genet* 2004;**21**:229–30.
- Beauchesne LM, Connolly HM, Ammash NM, Warnes CA. Coarctation of the aorta: outcome of pregnancy. *J Am Coll Cardiol* 2001;**38**:1728–33.
- Garvey P, Elovitz M, Landsberger EJ. Aortic dissection and myocardial infarction in a pregnant patient with Turner syndrome. *Obstet Gynecol* 1998;**91**:864.
- Weytjens C, Bove T, Van Der Niepen P. Aortic dissection and Turner's syndrome. *J Cardiovasc Surg* 2000;**41**:295–7.
- Nienaber CA, Fattori R, Mehta RH, Richartz BM, Evangelista A, Petzsch M, Cooper JV, Januzzi JL, Ince H, Sechtem U, Bosson E, Fang J, Smith DE, Isselbacher EM, Pape LA, Eagle KA, on Behalf of the International Registry of Acute Aortic D. Gender-related differences in acute aortic dissection. *Circulation* 2004;**109**:3014–21.
- Gillum RF. Epidemiology of aortic aneurysm in the United States. *J Clin Epidemiol* 1995;**48**:1289–98.
- Homme JL, Aubry MC, Edwards WD, Bagniewski SM, Shane Pankratz V, Kral CA, Tazelaar HD. Surgical pathology of the ascending aorta: a clinicopathologic study of 513 cases. *Am J Surg Pathol* 2006;**30**:1159–68.
- Gotzsche CO, Krag-Olsen B, Nielsen J, Sorensen KE, Kristensen BO. Prevalence of cardiovascular malformations and association with karyotypes in Turner's syndrome. *Arch Dis Child* 1994;**71**:433–6.
- Elsheikh M, Casadei B, Conway GS, Wass JA. Hypertension is a major risk factor for aortic root dilatation in women with Turner's syndrome. *Clin Endocrinol (Oxf)* 2001;**54**:69–73.

- 50 **Ostberg JE**, Donald AE, Halcox JP, Storry C, McCarthy C, Conway GS. Vasculopathy in Turner syndrome: arterial dilatation and intimal thickening without endothelial dysfunction. *J Clin Endocrinol Metab* 2005;**90**:5161–6.
- 51 **Robinson PN**, Arteaga-Solis E, Baldock C, Colod-Beroud G, Booms P, De Paepe A, Dietz HC, Guo G, Handford PA, Judge DP, Kielty CM, Loeys B, Milewicz DM, Ney A, Ramirez F, Reinhardt DP, Tiedemann K, Whiteman P, Godfrey M. The molecular genetics of Marfan syndrome and related disorders. *J Med Genet* 2006;**43**:769–87.
- 52 **Frias JL**, Davenport ML. Health supervision for children with Turner syndrome. *Pediatrics* 2003;**111**:692–702.
- 53 **Bondy CA**. Care of girls and women with turner syndrome: a guideline of the turner syndrome study group. *J Clin Endocrinol Metab* 2007;**92**:10–25.
- 54 **International Turner syndrome dissection registry**. <http://www.tssus.org/readweb.asp?wid=3092>.
- 55 **Rubin K**. Aortic dissection and rupture in Turner syndrome. *J Pediatr* 1993;**122**:670.
- 56 **Bartlema KA**, Hogervorst M, Akkersdijk GJ, Seelen J, Hoogland P, de Vries AC. Isolated abdominal aortic dissection in a patient with Turner's syndrome. *Surgery* 1995;**117**:116–17.
- 57 **Price WH**, Wilson J. Dissection of the aorta in Turner's syndrome. *J Med Genet* 1983;**2**:61–3.
- 58 **Hata J**. Ultrastructural and histochemical studies on aortic dissection aneurysm. *Myok Kangaku* 1986;**26**:493–8.
- 59 **Price WH**, Clayton JF, Collyer S, De Mey R, Wilson J. Mortality ratios, life expectancy and causes of death in patients with Turner's syndrome. *J Epidemiol Community Health* 1986;**40**:97–102.
- 60 **Hirose H**, Amano A, Takahashi A, Nagano N, Kohmoto T. Ruptured aortic dissecting aneurysm in Turner's syndrome: a case report and review of literature. *Ann Thorac Cardiovasc Surg* 2000;**6**:275–80.
- 61 **Chlumsky J**, Kolbel F, Buresova M, Svab P, Krutikova V, Koudelkova E, Pavel P, Srnsky V, Seemanova E, Zemkova J, Novotna D. [A dissecting aortic aneurysm in a female patient with Turner syndrome]. *Vnitr Lek* 2000;**46**:34–6.
- 62 **Meunier JP**, Jazayeri S, David M. Acute type A aortic dissection in an adult patient with Turner's syndrome. *Heart* 2001;**86**:546.
- 63 **Clement CI**, Brereton J, Clifton-Bligh P. Aortic dissection in Turner syndrome. *Med J Aust* 2004;**180**:584.

See your work published in *Journal of Medical Genetics*

Journal of Medical Genetics is only as good as its articles, so we work hard to support the authors who trust us to publish their work. Here are just a few reasons why you should send us your article:

- **Academic credibility** – You'll be published in one of the top medical genetics journals in Europe.
- **Maximum visibility for your article** – Your work will be seen by a wide international audience, both through the print journal (C 1500 readers per issue) and the website (C 42,000 unique visitors every month).
- **Hassle free peer review** – Our fast and efficient submission process involves only the best reviewers. The entire submission and peer review process is conducted online, saving you time and shortening the wait for your paper to be published.
- **Online First** – Your article may appear on the journal website as soon as it's accepted via our 'Online First' feature. Your colleagues could be reading your paper within days of you submitting it.

For more information or to submit an article visit www.jmg.bmj.com and click the **Online Submissions** button.