

Hirschsprung disease, associated syndromes and genetics: a review

J Amiel,¹ E Sproat-Emison,² M Garcia-Barcelo,³ F Lantieri,^{4,5} G Burzynski,⁶ S Borrego,⁷ A Pelet,¹ S Arnold,² X Miao,³ P Griseri,⁴ A S Brooks,^{6,8} G Antinolo,⁷ L de Pontual,¹ M Clement-Ziza,¹ A Munnich,¹ C Kashuk,² K West,² K K-Y Wong,³ S Lyonnet,¹ A Chakravarti,² P K-H Tam,³ I Ceccherini,⁴ R M W Hofstra,⁶ R Fernandez,⁷ for the Hirschsprung Disease Consortium

ABSTRACT

Hirschsprung disease (HSCR, aganglionic megacolon) represents the main genetic cause of functional intestinal obstruction with an incidence of 1/5000 live births. This developmental disorder is a neurocristopathy and is characterised by the absence of the enteric ganglia along a variable length of the intestine. In the last decades, the development of surgical approaches has importantly decreased mortality and morbidity which allowed the emergence of familial cases. Isolated HSCR appears to be a non-Mendelian malformation with low, sex-dependent penetrance, and variable expression according to the length of the aganglionic segment. While all Mendelian modes of inheritance have been described in syndromic HSCR, isolated HSCR stands as a model for genetic disorders with complex patterns of inheritance. The tyrosine kinase receptor *RET* is the major gene with both rare coding sequence mutations and/or a frequent variant located in an enhancer element predisposing to the disease. Hitherto, 10 genes and five loci have been found to be involved in HSCR development.

Harald Hirschsprung, a Danish paediatrician, first described in 1888 two unrelated boys who died from chronic severe constipation with abdominal distension resulting in congenital megacolon.¹ The absence of intramural ganglion cells of the myenteric and submucosal plexuses (Auerbach and Meissner plexuses, respectively) downstream of the dilated part of the colon was recognised as the cause of the disease in the 1940s.² This allowed a simple and reliable diagnostic confirmation from rectal suction biopsies using histochemical staining for acetylcholinesterase (AChE).³ In 1948, Swenson and Bill developed a surgical procedure⁴ and the survival of patients uncovered familial transmission of Hirschsprung disease (HSCR).⁵ In 1974, Bolande proposed the term neurocristopathy for syndromes or tumours involving the neural crest (NC) cells.⁶ HSCR resulting from an anomaly of the enteric nervous system (ENS) of NC origin is therefore regarded as a neurocristopathy.^{6–8}

Isolated HSCR appears to be of complex, non-Mendelian inheritance with low, sex-dependent penetrance, variable expression according to the length of the aganglionic segment and suggestive of the involvement of one or more gene(s) with low penetrance.^{5–9} These parameters must be taken into account for accurate evaluation of recurrence risk in relatives. With a relative risk as high as 200,

HSCR appears an excellent model to study common multifactorial diseases. The major susceptibility gene is *RET*, which is also involved in multiple endocrine neoplasia type 2 (MEN 2) and familial medullary thyroid carcinoma (FMTTC). Coding sequence mutations are identified in about 50% and 15% of familial and sporadic HSCR cases, respectively. The far most frequent HSCR predisposing event at the *RET* locus is a haplotype which comprises an SNP lying in an enhancer element of *RET* intron 1. The identification of modifier genes is currently underway by using various approaches and an international consortium has been settled in 2004 in order to achieve this goal.

HSCR occurs as an isolated trait in 70% of patients, is associated with a chromosomal abnormality in 12% of the cases, and with additional congenital anomalies in 18% of the cases.^{10–15} In the latter group of patients, some monogenic syndromes can be recognised. Indeed, thus far, genetic heterogeneity in HSCR has been demonstrated with 10 specific genes involved. The aim of this paper is to update a 6 year old review on clinical and molecular data about isolated and syndromic HSCR.

DEFINITION AND CLASSIFICATION

HSCR is a congenital malformation of the hindgut characterised by the absence of parasympathetic intrinsic ganglion cells in the submucosal and myenteric plexuses.² It is regarded as the consequence of the premature arrest of the craniocaudal migration of vagal neural crest cells in the hindgut between the fifth and 12th week of gestation to form the enteric nervous system (ENS) and is therefore regarded as a neurocristopathy.^{6–16} While the internal anal sphincter is the constant inferior limit, patients could be classified as short-segment HSCR (S-HSCR: 80% of cases) when the aganglionic segment does not extend beyond the upper sigmoid, and long-segment HSCR (L-HSCR: 20% of cases) when aganglionosis extends proximal to the sigmoid. Four HSCR variants have been reported: (1) total colonic aganglionosis (TCA, 3–8% of cases)¹⁷; (2) total intestinal HSCR when the whole bowel is involved¹⁷; (3) ultra-short segment HSCR involving the distal rectum below the pelvic floor and the anus¹⁸; (4) suspended HSCR, a controversial condition, where a portion of the colon is aganglionic above a normal distal segment.

¹ Université Paris 5-Descartes, Faculté de Médecine; INSERM U-781; AP-HP, Hôpital Necker-Enfant Malades, Paris, France;

² McKusick-Nathans Institute of Genetic Medicine, Johns Hopkins University School of Medicine, Baltimore, USA;

³ Division of Paediatric Surgery, Department of Surgery, Li Ka Shing Faculty of Medicine of the University of Hong Kong, Hong Kong SAR, China; ⁴ Laboratorio di Genetica Molecolare, Istituto G. Gaslini, L.go G. Gaslini 5, Italy;

⁵ Dipartimento di Scienze della Salute, Sezione Biostatistica, Università degli Studi di Genova, Genova, Italy; ⁶ Department of Genetics, University Medical Center Groningen, University of Groningen, Groningen, The Netherlands; ⁷ Unidad Clínica de Genética y Reproducción. Hospitales Universitarios Virgen del Rocío and Centro de Investigación Biomédica en Red de Enfermedades Raras (CIBERER), Sevilla, Spain;

⁸ Department of Clinical Genetics, Erasmus MC, Rotterdam, The Netherlands

Correspondence to: Dr Jeanne Amiel, INSERM U781 et Département de Génétique, Hôpital Necker-Enfants Malades, 149, rue de Sèvres 75743 Paris Cedex 15, France; amiel@necker.fr

Received 21 August 2007

Revised 21 August 2007

Accepted 27 August 2007

Published Online First

26 October 2007

CLINICAL FEATURES AND DIAGNOSIS

In most cases, the diagnosis of HSCR is made in the newborn period¹⁵ due to intestinal obstruction with the following features: (1) delayed of passage of meconium (>24 h after birth); (2) abdominal distension that is relieved by rectal stimulation or enemas; (3) vomiting; and (4) neonatal enterocolitis. Some patients are diagnosed later in infancy or in adulthood with severe constipation, chronic abdominal distension, vomiting, and failure to thrive.¹⁹ Finally, although a rare presentation, unexplained perforation of the caecum or appendix should make the diagnosis considered.

On abdominal x ray a distended small bowel and proximal colon, with absence of rectal gas, are common findings. The classical image is a dilated proximal colon with the aganglionic cone narrowing towards the distal gut. On barium enema a small rectum with uncoordinated contractions is seen. The transitional zone represents the site where the narrow aganglionic bowel joins the dilated ganglionic bowel. On a delayed plain x ray taken 24 h after the enema, barium retention is observed. Anorectal manometry shows absence of relaxation of the internal sphincter (rectal inhibitory reflex) in response to rectal distension.²⁰ The reliability of this test becomes excellent from day 12 after birth where the normal rectoenteric reflex is present.²¹ Suction rectal biopsy remains the gold standard for confirming the diagnosis in most cases demonstrating an increased acetyl cholinesterase activity.²² Nonetheless, full thickness rectal biopsy is the golden standard in reaching the diagnosis. Furthermore, seromuscular biopsies will be needed at operation to define the proximal limit of the aganglionic segment.

DIFFERENTIAL DIAGNOSES

Other causes of intestinal obstruction should be discussed when abdominal distension and failure to pass meconium occur in a newborn infant: (1) meconium ileus resulting from cystic fibrosis; (2) intestinal malformations such as lower ileal and colonic atresia, isolated or occasionally associated with HSCR, intestinal malrotation or duplication; (3) ENS anomalies grouped as chronic intestinal pseudo-obstruction syndromes; and (4) functional intestinal obstruction resulting from maternal infection, maternal intoxication or congenital hypothyroidism.

TREATMENT AND PROGNOSIS

The treatment of HSCR is surgical. After careful preoperative management, the underlying principle is to place the normal bowel at the anus and to release the tonic contraction of the internal anal sphincter. Since the initial protocol of Swenson described in 1948,⁴ a series of operative approaches, such as the Soave and Duhamel procedures, have been developed.^{23–24} A one stage procedure is possible when diagnosis is made early, before colonic dilatation, in short segment disease. Otherwise, a primary colostomy is required. For long segment disease and total colonic aganglionosis, temporary enterostomy is often the first step in management before definitive surgery. Laparoscopic and transanal pull-through techniques have been proposed more recently in HSCR surgery.²⁵ These techniques can provide patients with almost scarless surgery. Comparative long term results are pending.^{26–27} Neuronal precursor cells isolated from the developing human ENS may open the route to cell therapy.^{28–29} Fistula or stenosis of the anastomosis and enterocolitis are the main short term complications.³⁰ Long term complications include chronic constipation (10–15%) and

soiling.^{31–32} Mortality has been below 6% since the 1980s and may be related to short term complications or caused by the associated malformations.³¹ However, the treatment of children with TCA remains hazardous.^{33–34}

EPIDEMIOLOGY

The incidence of HSCR is estimated at 1/5000 live births.⁵ However, the incidence varies significantly among ethnic groups (1.0, 1.5, 2.1, and 2.8 per 10 000 live births in Hispanics, Caucasian-Americans, African-Americans, and Asians, respectively).¹⁵ S-HSCR is far more frequent than L-HSCR (80% and 20%, respectively).^{10–12} There is a sex bias with a preponderance of affected males and a sex ratio of 4/1.³⁵ Interestingly, the male:female ratio is significantly higher for S-HSCR (4.2–4.4) than for L-HSCR (1.2–1.9) (table 1).^{15–35}

MOLECULAR GENETICS IN ISOLATED HSCR

Several genes have been implicated in isolated HSCR, the two major ones being *RET* and *EDNRB*.

The RET signalling pathway

The first susceptibility locus was mapped to 10q11.2 in multigenerational families segregating HSCR as an incompletely penetrant autosomal dominant trait.^{36–37} This region had been targeted because of the observation of an interstitial deletion of chromosome 10q11 in patients with TCA and mental retardation.³⁸ The proto-oncogene *RET* (REarranged during Transfection), identified as disease causing in MEN 2^{39–40} and mapping in 10q11.2, was regarded as a candidate gene owing to: (1) co-occurrence of MEN 2A and HSCR in some families; and (2) expression in neural-crest derived cells. Consequently, *RET* gene mutations were identified in HSCR patients (fig 1).^{41–42} Over 100 mutations have been identified including large deletions encompassing the *RET* gene, microdeletions and insertions, nonsense, missense and splicing mutations.^{43–46} There is no mutational hot spot at variance with MEN 2A, where mutations occur in a cluster of six cysteines (exon 10: residues 609, 611, 618, 620; exon 11: residues 630, 634),^{39–40–47} and MEN 2B where the mutation is almost unique (M918T, exon 16, tyrosine kinase domain).^{48–51} In vitro, MEN 2 mutations have been shown to be activating mutations leading to constitutive dimerisation of the receptor and to transformation,⁵² while haploinsufficiency is the most likely mechanism for HSCR mutations.^{53–57} Biochemical studies demonstrated variable consequences of some HSCR mutations (misfolding, failure to transport the protein to the cell surface, abolished biological activity).^{54–56–58} However, a simple activating versus inactivating model of gene action is not sufficient to explain the co-occurrence of HSCR and MEN 2A in patients with a MEN 2A *RET* gene mutation.^{51–59}

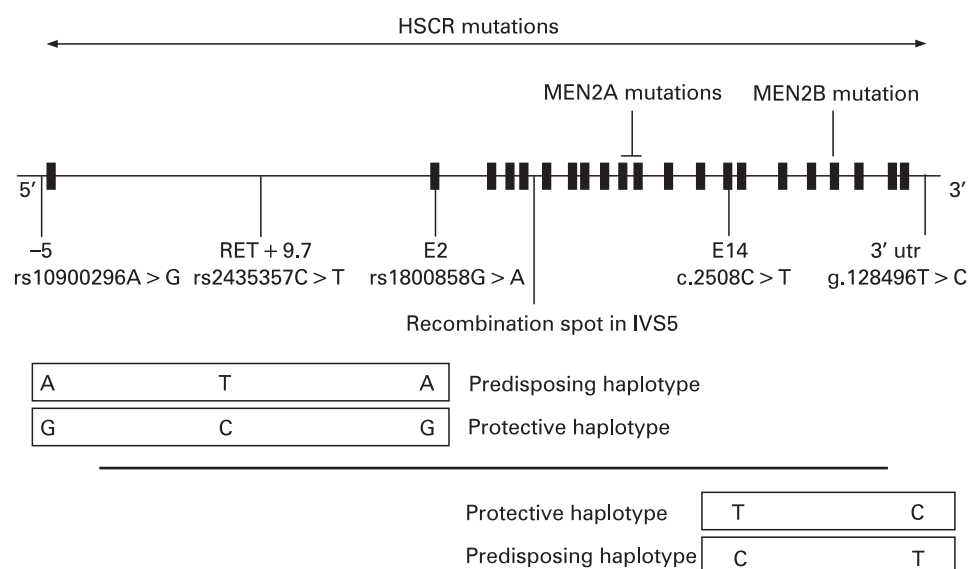
Table 1 Epidemiology and recurrence risk figures in HSCR

	L-HSCR	S-HSCR
% probands	19	81
Sex ratio (male:female)	1.75	5.5
Genetic model	Dominant	Multifactorial or recessive
Penetrance (%) (male:female)	52:40	17:4
Recurrence risk to sibs* (%)		
Male proband	17/13	5/1
Female proband	33/9	5/3

Relative risk = 200.

*Recurrence risk is given for male/female siblings, respectively.

Figure 1 Mutations, haplotypes and recombination spot at the *RET* locus.



Despite extensive mutation screening, a *RET* mutation is identified in only 50% of familial and 15–20% of sporadic HSCR cases.^{43 44 60 61} However, most families with few exceptions are compatible with linkage at the *RET* locus.⁶² Case-control and transmission disequilibrium test in several ethnic backgrounds had first pointed to a frequent SNP lying in exon 2 and leading to a silent change as over represented and transmitted in patients (fig 1).^{63–68} Later, the same observation was made for haplotypes comprising this SNP lying in exon 2 and an SNP at –5 from the transcription start site of *RET*.^{69–72} As there was no convincing evidence for a functional role of these two SNPs,^{71 73 74} the most likely hypothesis was that an ancient, low-penetrant founder locus was in linkage disequilibrium with the haplotype of the two SNPs previously identified and distant of about 25 kb.⁷⁰ Comparative genomics focused on conserved non-coding sequences and an SNP lying in intron 1 was shown associated to HSCR susceptibility, making a 20-fold greater contribution to risk than coding sequence mutations.⁷⁵ This T>C SNP lies in an enhancer-like sequence and the T allele reduces in vitro enhancer activity.⁷⁵ Moreover, this sequence drives reporter expression in tissue consistent with the one of *Ret* during mouse and zebra fish development.^{75 76} Interestingly, the frequency of the predisposing T allele varies according to HSCR prevalence in various ethnic backgrounds from about 20–50% in European and Chinese, respectively.^{75 77} The T allele high frequency in control populations emphasises, as speculated by the oligogenic model, the pivotal role of the *RET* gene in HSCR susceptibility despite low penetrance. Finally, the penetrance of the T allele for the HSCR trait is both dose-dependent and greater in males than in females.⁷⁵ Conversely, an SNP lying in the 3' UTR of the *RET* gene and lowering stability to *RET* mRNA degradation has been shown to be under transmitted in HSCR cases.⁷⁸ Again, this SNP lies on a haplotype that is of variable frequency according to ethnicity (about 8–4% in Caucasian and absent in Chinese).^{71 79 80} A recombination spot lies on intron 5 at the *RET* locus.^{59 66}

RET is a 1114 amino acid transmembrane receptor with a cadherin-like extracellular domain, a cysteine-rich region and a intracellular tyrosine kinase domain.⁸¹ The role of *Ret* in mice development has been expanded to kidney,^{82–84} spermatogenesis^{85–88} and Peyer's patch.^{89 90} Between the two *RET* major isoforms (*RET9* and *RET51*) with different C-terminal tails as

the result of alternative splicing, *RET9* is critical for both kidney and ENS development.⁹¹

GDNF, known as a major survival factor for many types of neurons, was shown to be the *RET* ligand by both phenotypic similarities between *Ret* –/– and *Gdnf* –/– knock-out mice,^{92–94} and xenopus embryo bioassays.⁹⁵ GDNF is a TGF- β related 211 residue protein, proteolytically cleaved to a 134 residue mature protein that homodimerise. To activate *RET*, GDNF needs the presence of a glycosylphosphatidylinositol (GPI)-linked co-receptor *GFRA1*.^{96 97} Four related GPI-linked co-receptors, *GFRA1–4*,⁹⁸ and four related soluble growth factor ligands of *RET* have been identified, namely: *GDNF*, *NTN*,⁹⁹ persephin (*PSPN*)¹⁰⁰ and artemin (*ARTN*).¹⁰¹ Specific combinations of these proteins are necessary for the development and maintenance of both central and peripheral neurons, and all can signal through *RET*. *GDNF* mutations have been identified in only six HSCR patients to date, and could be regarded as a rare cause of HSCR (<5%).^{102–104} Moreover, *GDNF* mutations may not be sufficient to lead to HSCR since 4/6 patients have additional contributory factors, such as *RET* mutations or trisomy 21.^{102 103} Similarly, an *NTN* mutation has been identified in one family, in conjunction with a *RET* mutation.¹⁰⁵ Finally, although *Gfra1* homozygous knock-out mice are phenotypically very similar to *Ret* and *Gdnf* –/– mice, no *GFRA1* mutations have been identified in HSCR patients except a deletion at the locus with incomplete penetrance in one family.^{69 106–109} Worth noting, *RET* exerts a pro-apoptotic effect that is inhibited by GDNF and some *RET* gene mutations may impair the control of this activity by GDNF.¹¹⁰

The endothelin signalling pathway

The endothelin pathway was first studied for its vasoconstrictive effect and putative role in hypertension. EDNRB and EDNRA are G-protein-coupled heptahelical receptors that transduce signals through the endothelins (EDN1, 2, 3).^{111 112}

A susceptibility locus for HSCR in 13q22 was pointed out for three main reasons: (1) a significant lod-score at 13q22 in a large inbred Old Order Mennonite community with multiple cases of HSCR^{113–115}; (2) de novo interstitial deletion of 13q22 in several patients with HSCR¹¹⁶; (3) synteny between the murine locus for *piebald-lethal* (*s^l*), a model of aganglionosis, and 13q22 in human. The critical role of the endothelin pathway in HSCR

was demonstrated with the finding that *piebald-lethal* was allelic to the *Ednrb* knock-out mouse and harboured an *Ednrb* mutation (table 2).¹¹⁷ Subsequently, an *EDNRB* missense mutation was identified in the Mennonite kindred (W276C).¹¹⁸ However, the W276C mutation was neither necessary (affected wild-type homozygotes) nor sufficient (non-affected mutant homozygotes) to cause HSCR, and penetrance was sex-dependent (greater in males than in females).¹¹⁸ *piebald-lethal* was considered a mouse model for WS4 in humans, and some of the Mennonite affected individuals had pigmentary anomalies and sensorineural deafness in addition to HSCR.^{113–114} This prompted a screen of the *EDNRB* gene in WS4, and homozygous mutations in a fraction of WS4 families were found.⁴⁴ At the same time, an *Edn3* mutation was identified in the *lethal spotting* (sl) natural mouse model for WS4¹¹⁹ and, subsequently, *EDN3* homozygote mutations were identified in WS4 in humans (table 2).^{120–121}

Both *EDNRB* and *EDN3* were screened in large series of isolated HSCR patients. While *EDN3* mutations were seldom found,¹³⁰ *EDNRB* mutations were identified in approximately 5% of the patients.^{126–129} It is worth mentioning that the penetrance of *EDN3* and *EDNRB* heterozygous mutations is incomplete in those HSCR patients, de novo mutations have not hitherto been observed, and that S-HSCR is largely predominant. Interstitial 13q22 deletions encompassing the *EDNRB* gene in HSCR patients makes haploinsufficiency the most likely mechanism for HSCR (table 3). Although *EDNRB* binds all three endothelins, the similarity of phenotype of the *Ednrb* knock-out mice to that of the *Edn3* knock-out mice suggests that *EDNRB*'s major ligand is *EDN3*.

Preproendothelins are proteolytically cleaved by two related membrane-bound metalloproteases to give rise to the mature 21-residue endothelin. *Ece1* processes only *Edn1* and *Edn3*. *Ece1* knock-out mice show craniofacial defects and cardiac abnormalities in addition to colonic aganglionosis.¹³² A heterozygous

ECE1 mutation has been identified in a single patient combining HSCR, craniofacial and cardiac defects (R742C).¹³¹

SOX10

The last known mouse model for WS4 in human is *dominant megalon* (*Dom*), homozygous *Dom* mutation being embryonic lethal.¹⁵² The *Dom* gene is *Sox10*, a member of the SRY (sex determining factor)-like, high mobility group (HMG) DNA binding proteins.¹²⁵ Subsequently, truncating heterozygote *SOX10* mutations have been identified in patients with WS4,^{122–124} Yemenite deaf-blind-hypopigmentation syndrome¹⁵³ and WS2 (Bondurand *et al* in *Am J Hum Genet* website) but also in patients presenting in addition neurological impairment due to central and peripheral dysmyelination.^{67–123} The latter combination is known as PCWH for Peripheral demyelination-Central dysmyelinating leucodystrophy-Waardenburg syndrome and Hirschsprung disease. Genotype-phenotype correlation relies on nonsense-mediated decay being effective (WS4) or not (PCWH).¹⁵⁴ The penetrance of the HSCR trait appears to be high, although sibs sharing a mutation and discordant for HSCR have been described in one family.¹²⁴ Therefore, *SOX10* is unlikely to be a major gene in isolated HSCR.

Interaction between pathways

Ret and *Ednrb* signalling pathways were considered biochemically independent. However, G-protein-coupled receptors and tyrosine kinase receptors could be engaged in crosstalk. Moreover an HSCR patient heterozygote for weak hypomorphic mutations in both *RET* and *EDNRB* has recently been reported.¹⁵⁵ Each mutation was inherited from a healthy parent. Genetic interactions between *EDNRB* and *RET* have been demonstrated in the Mennonite population where HSCR predisposition is high (incidence of 1/500).^{118–156} Finally, no complementation of aganglionosis could be observed in mouse

Table 2 Genes involved in HSCR in humans and known mouse models of megacolon

Gene	Human					Mouse		
	Map location	Mode of inheritance	Phenotype in mutants	Penetrance of the HSCR trait	Refs	Natural mutant	Knockout	Refs
<i>RET</i>	10q11.2	AD	HSCR	70% in males and 50% in females for CDS mutations	43, 44, 60, 61	–	L Renal agenesis	82
<i>GDNF</i>	5p13	AD	HSCR	5 cases reported Low penetrance	102–104	–	L Renal agenesis	92–94
<i>NTN</i>	19p13	AD	HSCR	1 case reported	105	–	–	
<i>SOX10</i>	22q13	AD	WS4	About 80%	122–124	Dom (AD)	L Coat spotting	125
<i>EDNRB</i>	13q22	AR/AD	WS4/HSCR	Low	118, 126–129	<i>s'</i> (AR)	S Coat spotting	117
<i>EDN3</i>	20q13	AR/AD	WS4/HSCR	1 case reported	130	<i>ls</i> (AR)	S Coat spotting	119
<i>ECE1</i>	1p36	AD	HSCR CF and cardiac defect	1 case reported	131	–	S Coat spotting Craniofacial defects	132
<i>ZFHX1B (SIP1)</i>	2q22	AD	MCA-MR, facial gestal,	60%	133–135	–	Letal at gastrulation	136
<i>PHOX2B</i>	4p12	AD	CCHS	20%	137, 138	–	TIA No ANS Ventilatory anomalies in <i>Phox2b</i> ^{+/–}	139, 140
<i>TCF4</i>	18q21	AD	Epileptic encephalopathy	1 case	141–143	–	Early lethality Abnormal maturation of lymphocytes	144, 145

AD, autosomal dominant; ANS, autonomic nervous system; AR, autosomal recessive; CF, craniofacial; L, long-segment megacolon; MR, mental retardation; S, short-segment megacolon; Spo, sporadic; *s'*, *Piebald lethal*; *ls*, *lethal spotting*; TIA, total intestinal aganglionosis.

Table 3 Recurrent chromosomal anomalies with HSCR as a feature

Chromosome	Key features	Number of reports	Gene	References
Tri 21	Down syndrome, S-HSCR, 5.5 to 10.5 male: female sex ratio	2–10% of HSCR cases	?	5, 11–15
Del 10q11	Mental retardation, L-HSCR	2 cases	<i>RET</i>	38, 146
Del 13q22	Mental retardation, growth retardation, dysmorphic features, S-HSCR	>10 cases	<i>EDNRB</i>	116
Del 2q22-q23	Postnatal growth retardation and microcephaly, mental retardation, epilepsy, dysmorphic features, HSCR*	>10 cases	<i>ZFXH1B</i>	133–135, 147, 148
Del 17q21		>1 case	?	149
Dup 17q21-q23	MCA/MR	4 cases	?	150
Tri 22pter-q11	Cat eye syndrome		?	151

*Both S-HSCR and L-HSCR have been observed.

inter crosses between hypomorphic piebald alleles of *Ednrb* (*Ednrb^{s/s}*) and a null allele of *Ret*.¹⁵⁶

Sox10 is involved in cell lineage determination and is capable of transactivating *MITF* synergistically with *PAX3*.¹⁵⁷ Similarly, *Ednrb* transcripts are either absent or drastically reduced in *Dom^{-/-}* and *Dom^{+/-}* mice, respectively.¹⁵⁸ *Sox10;Ednrb* and *Sox10;Edn3* double mutants have a severe ENS defect with no enteric progenitor cells extending beyond the stomach at all embryonic stages studied.¹⁵⁹ Interestingly, genetic interactions for the HSCR trait have been shown between *RET* and *PHOX2B* and *BBS* genes responsible when mutated for CCHS and Bardet-Biedl syndromes, respectively.¹⁴⁸ Such correlation was not found between *RET* and *SOX10*. Along these lines, a genome-wide screen aimed at localising modifier genes for the aganglionosis of *Dom* mice did not point to the *Ret* locus but, among others, a locus encompassing the *PHOX2b* gene.¹⁶⁰

Taking it all together, several general comments can be made: (1) *RET* is the major gene in HSCR with either CDS mutations or, more frequently, a low penetrant SNP lying in an enhancer element within intron 1; (2) *RET* mutation penetrance is incomplete and sex-dependant; (3) genotype–phenotype correlation is poor; (4) HSCR is genetically heterogeneous and due to mutations in distinct pathways; (5) some patients with mutations in more than one HSCR susceptibility gene are known (*RET+GDNF*, *RET+NTN*, *RET+EDNRB*); (6) the *RET* gene plays a role in HSCR penetrance of some but not all syndromic HSCR (see below).

MULTIGENIC INHERITANCE OF ISOLATED HIRSCHSPRUNG DISEASE

As mentioned above, *RET* plays a key role in HSCR genesis and multiple genes may be required to modulate clinical expression. On the other hand, genetic heterogeneity where mutation in one of several genes is sufficient for phenotypic expression of HSCR has been demonstrated (*RET*, *EDNRB*, *EDN3*, *ECE1*). Segregation studies in HSCR showed that the recurrence risk in siblings varies from 1.5–33% depending on the gender and the length of the aganglionic segment in the proband, and the gender of the sibling (table 1).^{5–35} Consequently, HSCR has been assumed to be a sex modified multifactorial disorder, the effect of genes playing a major role as compared to environmental factors (relative risk of 200).

According to the segregation analysis where an autosomal dominant model in L-HSCR and a multifactorial model in S-HSCR were more likely, different approaches have been chosen to test these hypotheses in L-HSCR and S-HSCR independently.

- Linkage analysis in 12 HSCR families with three or more affected individuals in two or more generations where L-HSCR is largely predominant.⁶² All but one family showed

linkage to the *RET* locus. Mutational analysis identified a nonsense or missense mutation at highly conserved residue in six families, a splice mutation in two families and no coding sequence variation in three families. Linkage to a novel locus in 9q31 was identified only in families with no or hypomorphic *RET* gene mutation. Therefore, a severe *RET* mutation may lead to phenotypic expression by haploinsufficiency while hypomorphic *RET* mutations would require the action of other mutations.

- A sib-pair analysis in 49 families with S-HSCR probands.¹⁶¹ This studies shows that only three loci on chromosomes 3p21, 10q11 and 19q12 are both necessary and sufficient to explain the incidence and sibling recurrence risk in HSCR. A multiplicative risk across loci with most affected individuals being heterozygotes at all three loci seems the best genetic model. Finally, linkage to 9q31 was confirmed in the sib-pairs with no or hypomorphic *RET* mutation.
- A genome-wide association study was conducted in 43 Mennonite family trios and identified a susceptibility locus on 16q23 in addition to the loci of the two predisposing genes in this population (*RET* and *EDNRB* at 10q11.2 and 13q22, respectively).¹⁵⁶
- Linkage analysis in a multigenerational HSCR family where the *RET* gene had been previously excluded, showed linkage to 4q31-q32.¹⁶²

The route to the identification of modifier genes is now based on various approaches. A differential screen for ENS expressed genes was conducted by a 22 000 probe DNA micro array of embryonic *Ret^{+/+}* and *Ret^{-/-}* mice and identified over 300 genes over expressed in *Ret^{+/+}* mice.²⁹ These genes are regarded as critical for enteric neurogenesis and therefore potential candidates in HSCR. By syntenicity, some lie at candidate modifier loci for isolated HSCR. Other approaches undertaken by the HSCR Consortium are microarrays of RNAs from microdissection of enteric neurons and glia on the one hand and 500 k SNP genotyping in trios on the other hand.

SYNDROMIC HSCR

HSCR occurs as an isolated trait in 70% of cases. A chromosomal abnormality is associated in 12% of cases, trisomy 21 being by far the most frequent (>90%). Associated congenital anomalies are found in 18% of the HSCR patients. The one occurring at a frequency above that expected by chance include gastrointestinal malformation, cleft palate, polydactyly, cardiac septal defects and craniofacial anomalies.^{13–14} The higher rate of associated anomalies in familial cases than in isolated cases (39% vs 21%) strongly suggests syndromes with Mendelian inheritance.¹⁴ Assessment of all HSCR patients by a trained dysmorphologist should provide a careful evaluation for recognisable syndromes.

Chromosomal anomalies

A large number of chromosomal anomalies have been described in HSCR patients. Free trisomy 21 (Down syndrome) is by far the most frequent, involving 2–10% of ascertained HSCR cases.^{5 11–15} In these cases, both the unbalanced sex ratio (5.5–10.5:1 male:female) and the predominance of S-HSCR are even greater than in isolated HSCR. Over-expression of gene(s) on chromosome 21 and predisposing to HSCR has been hypothesised and a susceptibility gene mapping to 21q22 postulated in a Mennonite kindred.¹¹⁴ However, these data were not confirmed.¹⁵⁶ Hitherto, coding sequence mutations in genes predisposing to HSCR, *RET*, *EDNRB* and *GDNF*, respectively, were found in only three patients with Down syndrome and HSCR.^{103 163} However, the common HSCR predisposing *RET* hypomorphic allele is over represented in patients with Down syndrome and HSCR when compared to patients without HSCR.¹⁴⁸

Some chromosomal interstitial deletions reported in combination with HSCR, have been important for the identification of HSCR predisposing genes, namely: (1) 10q11.2 interstitial deletion observed in a few patients with L-HSCR or TCA^{38 146} leading to the mapping and identification of the first HSCR predisposing gene (*RET*); (2) 13q22.1–32.1 interstitial deletion in patients with S-HSCR leading to the mapping of the second gene (*EDNRB*)^{164–166}; (3) 2q22–23 interstitial deletion syndrome in patients with a multiple congenital anomaly–mental retardation (MCA-MR) syndrome with HSCR or severe chronic constipation further delineated as Mowat-Wilson syndrome (table 3),^{133 134 147} leading to the identification of the *ZFHX1B* gene (previously named *SIP1* gene).¹³⁵

Rarer chromosomal anomalies reported in combination with HSCR are summarised in table 3. DiGeorge syndrome, mosaic trisomy 8, XXY chromosomal constitution, partial duplication of chromosome 2q, tetrasomy 9p, and 20p deletion, have been observed at least once with HSCR. Interestingly, a patient with S-HSCR, postnatal growth retardation, mild developmental delay, dysmorphic facial features and a deletion at 4p12 encompassing the *PHOX2B* gene has been reported.¹⁶⁷

Syndromes and associated anomalies

Both the recognition of known entities and the delineation of novel ones including HSCR as a feature are of importance for disease prognosis, accurate genetic counselling and search for candidate genes. Syndromes reported associated with HSCR are numerous. Some associations are well characterised with a penetrance of HSCR ranging from 5% to >80% (table 2). For rare disorders, whether an association with HSCR observed once is meaningful or occurred by chance alone is not possible to decide. These conditions are summarised in table 4. Both frequent and occasional associations may be of interest for the identification of susceptibility genes to HSCR.

Syndromes frequently associated with HSCR: neurocristopathies

The NC is a transient and multipotent embryonic structure that gives rise to neuronal, endocrine and paraendocrine, craniofacial, conotruncal heart and pigmentary tissues.⁷ Neurocristopathies encompass tumours, malformations and single or multifocal anomalies of tissues mentioned above with various combinations. MEN 2, neuroblastoma (NB) conotruncal heart defects and Waardenburg syndromes illustrate each of these categories, and are associated with HSCR.

Multiple endocrine neoplasia type 2 and familial medullary thyroid carcinoma

Familial medullary thyroid carcinoma (FMTC), MEN type 2A (MEN 2A) and type 2B (MEN 2B) are cancer predisposition syndromes with an autosomal dominant mode of inheritance. MEN 2A is defined by an age-related predisposition to medullary thyroid carcinoma (MTC, 70% by the age of 70 years), pheochromocytoma (50% of cases) and hyperplasia of the parathyroid glands (15–35%). In addition to MTC and pheochromocytoma, individuals with MEN 2B present with oral neuromas, marfanoid habitus and hyperganglionosis of the hindgut.²⁰⁸ Germline missense mutations of the *RET* gene have been identified in MEN 2A, MEN 2B and FMTC. Both FMTC and MEN 2A can be associated with HSCR in some families.^{47 175–181} Interestingly, these families present a germline *RET* mutation of the MEN 2A or FMTC type (see below).^{47 176–181} This raises the question of whether all individuals with HSCR, regardless of non-contributive family history, should be screened for *RET* exon 10 and 11 mutations to rule out cancer predisposition (3/160 cases in our series with C609W, C611R and C620R *RET* gene mutations, respectively).

Neuroblastoma

Neuroblastoma (NB) is the most frequent solid tumour in childhood with an incidence of 1/10 000. The tumour can arise at any site of the sympathetic chain or the adrenal medulla (both originating from NCC). In some families, tumour predisposition segregates through generations with incomplete penetrance.^{209–211} NB is found associated to HSCR and congenital central hypoventilation (CCHS, see below) in various combinations and, in each combination, heterozygous mutations of the paired-like homeobox 2B gene (*PHOX2B*) have been identified.^{137 212–217} However, germline *PHOX2B* mutations remain rare in sporadic, isolated NB.^{215 216}

Congenital central hypoventilation syndrome (CCHS, MIM 209880).

Initially termed Ondine's curse, CCHS is a rare, life-threatening condition characterised by abnormal ventilatory response to hypoxia and hypercapnia due to failure of autonomic respiratory control.²¹⁸ CCHS is not per se a neurocristopathy due to the involvement of both the central and peripheral autonomic nervous system. CCHS patients often present symptoms resulting from a broader dysfunction of the autonomic nervous system and predisposition to neural crest cell derived tumours (5–10% of CCHS cases, neuroblastoma, ganglioblastoma, ganglioneuroma).^{209 219–221} Haddad syndrome (MIM 209880) is defined by the association of HSCR and CCHS and is found in about 20% of CCHS patients.^{138 172 173} In these cases, L-HSCR (including TCA) is the most frequent, and the sex ratio is almost equal at variance to what is observed in isolated HSCR.²²² *PHOX2B* is the disease causing gene with de novo heterozygous mutation in the proband,¹⁷⁴ the far most frequent being in frame duplication leading to polyalanine expansion.^{223 224} Parents of patient with molecularly proven CCHS must be tested for accurate genetic counselling as about 10% carry a somatic mosaic¹³⁷ and some parents may develop late onset CHS.²²⁵ Finally, genotype/phenotype correlations allow the detection of patients with a high risk to develop tumours (and carry a frameshift mutation) and reassurance about tumour predisposition to those carrying a polyalanine expansion.¹³⁷

Table 4 Syndromes associated with HSCR

	Syndromes	MIM	Key features	References
Syndromic NCC disorders	WS4 (Shah-Waardenburg)	277580	Pigmentary anomalies (white forelock, iris hypoplasia, patchy hypopigmentation)	118, 120–122, 168
	Yemenite deaf-blind-hypopigmentation	601706	Hearing loss, eye anomalies (microcornea, coloboma, nystagmus), pigmentary anomalies	153
	BADS	227010	Hearing loss, hypopigmentation of the skin and retina	169
	Piebaldism	172800	Patchy hypopigmentation of the skin	170, 171
	Haddad	209880	Congenital central hypoventilation	172–174
	MEN2A		Medullary thyroid carcinoma, pheochromocytoma, hyperplasia of the parathyroid	47, 175–181
	Riley-Day	223900	Autonomic nervous system anomalies	
HSCR mandatory	Goldberg-Shprintzen	235730	Mental retardation, polymicrogyria, microcephaly, CF, coloboma, facial dysmorphic features	182–184
	HD with limb anomalies	235740	Polydactyly, unilateral renal agenesis, hypertelorism, deafness	185
		235750	Postaxial polydactyly, ventricular septal defect	186
		235760	Hypoplasia of distal phalanges and nails, dysmorphic features	187
		604211	Preaxial polydactyly, heart defect, laryngeal anomalies	188
		306980	Brachydactyly type D	189
	BRESHEK		Brain abnormalities, Retardation, Ectodermal dysplasia, Skeletal malformation, Hirschsprung disease, Ear/eye anomalies, Kidney dysplasia	190
	Mowat-Wilson	235730	Mental retardation, microcephaly, epilepsy, facial gestalt, hypospadias, renal anomalies, ACC, CCD	135, 148, 191–193
	Bardet-Biedl syndrome and/or	209900	Pigmentary retinopathy, obesity, hypogenitalism, mild mental retardation, postaxial polydactyly	194, 195
	Kauffman-McKusick	236700	Hydrometrocolpos, postaxial polydactyly, congenital heart defect	196
HSCR occasionally associated	Smith-Lemli-Opitz	270400	Growth retardation, microcephaly, mental retardation, hypospadias, 2–3 toes syndactyly, dysmorphic features	197
	Cartilage-hair hypoplasia	250250	Shortlimb dwarfism, metaphyseal dysplasia immunodeficiency	198
	HSAS/MASA	307000	Hydrocephalus, aqueductal stenosis, spasticity adducted thumbs, ACC, mental retardation	199
HSCR rarely associated	Fukuyama congenital muscular dystrophy	253800	Muscular dystrophy, polymicrogyria, hydrocephalus, MR, seizures	200, 201
	Clayton-Smith	258840	Dysmorphic features, hypoplastic toes and nails, ichthyosis	202
	Kaplan	304100	Agenesis of corpus callosum, adducted thumbs, ptosis, muscle weakness	203
	Okamoto	308840	Hydrocephalus, cleft palate corpus callosum agenesis	204
	Werner mesomelic dysplasia	188770		205, 206
	Pitt-Hopkins	610954	Epileptic encephalopathy, facial dysmorphic features, bouts of hyperventilation, dysautonomia	141–143
	Jeune asphyxiating thoracic dystrophy	208500		207
	Pallister-Hall (CAVE)	140510		
Miscellaneous associations	Fryns	229850		
	Aarskog	100050		
	Fronto-nasal dysplasia	136760		
	Osteopetrosis			
	Goldenhar	164210		
	Lesch-Nyhan	308000		
	Rubinstein-Taybi	180849		
	Toriello-Carey	217980		
	SEMDJL	271640		

Adapted from: Scriver CM *et al.* *The metabolic and molecular bases of inherited diseases*. 8th ed. McGraw-Hill, pp 6231–55.

Waardenburg syndromes (WS) and related pigmentary anomalies

WS, an autosomal dominant condition, is by far the most frequent condition combining pigmentary anomalies and sensorineural deafness (1/50 000 live births and 2–5% of all congenital deafness), resulting from the absence of melanocytes of the skin and the stria vascularis of the cochlea.²²⁶ WS is clinically and genetically heterogeneous (MIM 193500, MIM 148820, MIM 193510).²²⁷ The combination of HSCR with WS defines the WS4 type (Shah-Waardenburg syndrome, MIM 277580), a genetically heterogeneous condition. Indeed, homozygous mutations of the endothelin pathway^{118 120 121 168} and heterozygous *SOX10* mutations have been identified in WS4 patients.¹²² Patients carrying a *SOX10* mutation may also present with CNS involvement including seizures, ataxia, and demyelinating peripheral and central neuropathies^{123 228} and WS2 (Bondurand *et al* in *Am J Hum Genet* website).

Related syndromes associating pigmentary anomalies and HSCR include: (1) Yemenite deaf-blind hypopigmentation syndrome (MIM 601706), a *SOX10* mutation having been reported in one of these families¹⁵³; (2) Black Locks-Albinism-Deafness syndrome (BADS, MIM 227010) with TCA-HSCR in one case¹⁶⁹; (3) aganglionic megacolon associated with familial piebaldism (MIM 172800)^{170 171}; (4) HSCR and profound congenital deafness but with no other WS features has also been reported.²²⁹

Other neurocristopathies

Familial dysautonomia syndrome (FDS, Riley-Day syndrome, MIM 223900) has been reported once in association with HSCR. Although it could have arisen by chance alone, it is interesting to note that FDS maps to 9q31 where a susceptibility locus for HSCR has been identified. Other occasional associations

reported thus far include cleft lip with or without cleft palate,²³⁰ neural tube defects (myelomeningocele)²³¹ and neurofibromatosis type I.²¹⁰ The significance of these associations is not yet established.

Other syndromes with HSCR as a frequent feature

Mowat-Wilson syndrome (MIM 235730)

Mowat-Wilson syndrome (MWS) is an MCA-MR condition first delineated among the heterogeneous group of patients with HSCR and MR.¹³⁴ The condition is associated with microcephaly, epilepsy, a facial gestalt and severe mental retardation. The spectrum of possibly associated malformations is wide and encompasses, in decreasing frequency order, hypospadias, renal anomalies, congenital cardiac defect, agenesis/hypoplasia of the corpus callosum and HSCR.^{148–193} Heterozygous de novo deletions encompassing the *ZFHX1B* (zinc finger homeo box 1B) gene or truncating mutations within the gene are found in over 100 cases.^{135–191–192} Some rare splicing and missense mutations have also been reported.¹⁴⁸ Loss of function by haploinsufficiency is the disease causing mechanism in humans. *ZFHX1B* acts as a transcriptional repressor of smad protein targets and has key functions in early embryonic development in several animal models.^{94–136–232} A knock-out restricted to NCC precursors in mice demonstrated a wide range of anomalies in NCC derivatives.²³³

Goldberg-Shprintzen syndrome (MIM 609460)

This autosomal recessive MCA-MR syndrome combines HSCR, moderate mental retardation, microcephaly, polymicrogyria, facial dysmorphic features (hypertelorism, prominent nose, synophrys, sparse hair), cleft palate and iris coloboma.^{182–183} The disease causing gene *KIAA1279* has been identified in a large consanguineous family and encodes a protein of unknown function.¹⁸⁴ GSS is a rare condition within the group of patients with MR and HSCR. Several reports with variable association of microcephaly, iris coloboma, cleft palate and mental retardation, and regarded as possible variants GSS, are unlikely allelic conditions.^{234–235}

HSCR with limb anomalies

Several rare syndromes with HSCR and distal limb anomalies (polydactyly or hypoplasia) have been reported. These are: (1) HSCR with polydactyly, unilateral renal agenesis, hypertelorism and congenital deafness (MIM 235740)¹⁸⁵; (2) HSCR, postaxial polydactyly and ventricular septal defects (MIM 235750)¹⁸⁶; (3) HSCR, hypoplasia of the distal phalanges and nails and mild dysmorphic features (MIM 235760)¹⁸⁷; (4) HSCR with preaxial polydactyly, heart defect and laryngeal anomalies (MIM 604211)¹⁸⁸; (5) HSCR with brachydactyly type D (MIM 306980)¹⁸⁹; (6) HSCR with brachydactyly, macrocephaly and vertebrae anomalies¹⁹⁰; (7) BRESHEK syndrome²³⁶; and (8) Werner mesomelic dysplasia.^{205–206}

Bardet-Biedl syndrome (MIM 209900) and McKusick-Kauffman syndrome (MIM 236700)

Bardet-Biedl syndrome (BBS) is characterised by progressive pigmentary retinopathy, obesity, hypogenitalism, renal involvement (including cysts, renal cortical loss or reduced ability to concentrate urine), mild mental retardation and postaxial polydactyly of the hands and feet. BBS is genetically heterogeneous with at least 12 loci and 10 genes identified, all involved in ciliary function.²³⁷ HSCR has been reported in several BBS cases.^{194–195} McKusick-Kauffman syndrome (MKKS) is a rare

condition, allelic to BBS and characterised by hydrometrocolpos, postaxial polydactyly and congenital heart defect. HSCR is found in 10% of cases.¹⁹⁶ Mutations in the *MKKS/BBS6* gene, encoding a chaperonin protein, were identified in some BBS patients confirming that both conditions are allelic.^{238–239} Jeune syndrome, also ascribed to a gene involved in the ciliary function, has been occasionally associated to HSCR.²⁰⁷

Smith-Lemli-Opitz syndrome (MIM 270400)

Smith-Lemli-Opitz syndrome (SLO) is characterised by pre- and postnatal growth retardation and microcephaly, severe mental retardation, facial dysmorphic features, hypospadias and syndactyly between toes 2 and 3. SLO results from cholesterol metabolic impairment with mutation of the 7-dehydro-cholesterol reductase gene (*DHCR7*, chromosome 11q12-q13).^{240–241} HSCR is observed in a significant number of severe SLO patients.¹⁹⁷

Cartilage-hair hypoplasia syndrome (MIM 250250)

The skeletal dysplasia cartilage-hair hypoplasia syndrome (CHH), first described in the Old Order Amish community, combines metaphyseal dysplasia with short limb dwarfism, fine, sparse and blond hair, transient macrocytic anaemia and immunodeficiency. HSCR is associated in approximately 10% of the cases.¹⁹⁸ The gene *RMRP* has been mapped to chromosome 9p13.²⁴² Interestingly, HSCR has been reported in the Holmgren-Connor syndrome (MIM 211120) which may be allelic to CHH.

The *RET* gene plays a pivotal role in both isolated and syndromic HSCR. Indeed, epistatic interactions with the common *RET* hypomorphic allele has been demonstrated for HSCR predisposition in Down, CCHS and BBS.^{148–243} Conversely, the role of the *RET* hypomorphic allele is not significant in MWS and WS4 due to *SOX10* mutation.¹⁴⁸ Of note, a case-control study in a Chinese population identified an SNP in intron 2 of *PHOX2B* (IVS2+100) as over represented in the HSCR group of patients.²⁴⁴

Miscellaneous observations

This can be include; (1) syndromes with myopathy^{200–201}; (2) syndromes with dermatological findings²⁰²; and (3) syndromes with central nervous system anomalies, among which the HSAS/MASA spectrum ascribed to mutations in the X-linked *L1CAM* gene. Indeed, at least five different mutations in *L1CAM* have been identified in patients with hydrocephalus and HSCR.¹⁹⁹ Interestingly, *L1cam* is an ENS-expressed gene.²⁹ The question of *L1CAM* being a modifier gene in HSCR has been raised with no definitive answer given thus far.^{245–246} Other rare associations include the finding of HSCR with Fryns, Aarskog, Jeune asphyxial thoracic dystrophy, Joubert, frontonasal dysplasia, osteopetrosis, Goldenhar, Lesch-Nyhan, Rubinstein-Taybi, Toriello-Carey, Pallister-Hall, spondylo-epimetaphyseal dysplasia with joint laxity (SEMDJL, MIM 271640), persistent müllerian duct syndromes, and asplenia with cardiovascular anomaly.

Associated anomalies

A wide spectrum of additional isolated anomalies have been described among HSCR cases, with an incidence varying from 5–30% according to series.^{10–11–13–247–250} No constant pattern is observed and these anomalies include distal limb, sensorineural, skin, central nervous system, genital, kidney and cardiac malformations. However, cardiac defects, and mostly atrio- or

ventriculoseptal defects, are found with an incidence of 5% of HSCR cases, once removed patients with trisomy 21 and HSCR. Renal dysplasia or agenesis was reported in FMTC²⁵¹ and found in 4.4% in a series of 160 HSCR cases and may still be underestimated (personal data). This is of interest since homozygous knock-out mice for genes involved in the *Ret* signalling pathway present with renal agenesis/dysplasia in addition to megacolon.⁸² Genital anomalies including hypospadias are reported in up to 2–3% of HSCR patients. Gastrointestinal malformations such as Meckel diverticulum, pyloric stenosis, single umbilical artery, inguinal hernia or small bowel atresia are also found.^{252–254} Finally, facial dysmorphic features seem extremely frequent when looked for. These data highlight the importance of a careful assessment by a clinician trained in dysmorphology for all newborns diagnosed with HSCR. Skeletal x ray, cardiac and urogenital ultrasound survey should be systematically performed. The observation of one additional anomaly to HSCR should prompt chromosomal studies and/or molecular karyotyping.

The unanswered question of sex-dependent penetrance in HSCR

Expression and penetrance of a *RET* mutation is variable and sex-dependent within HSCR families. In large series, the estimated penetrance is 72% in males and 51% in females.⁴⁴ Accordingly, the penetrance of the HSCR predisposing T allele for the HSCR trait is greater in females than in males.⁷⁵ A significant parent-of-origin effect at the *RET* locus, 78% of shared *RET* alleles by affected sibs being maternally derived, could explain the sex difference in HSCR expression. Epigenetic effects at the *RET* locus have been hypothesised. Of note, a sex difference in disease expressivity (that is, length of the aganglionic segment) of *Ret*^{+/-}; *Ednr*^{b/s} mice has been observed.²⁵⁵ None of the genome wide scans performed in HSCR families identified a locus on the X chromosome thus far. However, a differential screen for ENS expressed genes performed in mice pointed to several X-linked genes.²⁹ Finally, the observation of a skewed sex ratio in *RET*-independent syndromic HSCR (that is, MWS and WS4) suggests that the sex bias observed cannot entirely rely on a gender effect at the *RET* locus.¹⁴⁸

GENETIC COUNSELLING

HSCR is a sex-modified multifactorial congenital malformation with an overall recurrence risk in sibs of the proband of 4% (relative risk = 200). In isolated HSCR, adequate relative risk figures will be provided by taking into account the sex and length of the aganglionic segment in the proband and the gender of the sibling (2–33%). According to Carter's paradox, the highest recurrence risk is for a male sibling of a female proband with L-HSCR (table 1). According to poor genotype–phenotype correlation thus far, the benefit of mutation screening for HSCR patients appears low except for systematic testing of exon 10 and 11 of the *RET* gene, owing to cancer predisposition of MEN2A mutations. This, however, is still not routine practice in most countries.

Many HSCR cases are associated with other congenital anomalies. In these cases, the long term prognosis is highly dependent on the severity of the associated anomalies. Several known syndromes have straight Mendelian inheritance. This emphasises the importance of careful assessment by a clinician trained in syndromology of all newborns diagnosed with HSCR.

Acknowledgements: We thank the HSCR patients and their families, and the French Hirschsprung Disease Association (AFMAM), for their cooperation and active

participation over 10 years. We sincerely acknowledge colleagues from all over the world for providing us samples as well as all the students and collaborators of the groups who joined in a consortium on Hirschsprung disease.

Competing interests: None declared.

REFERENCES

- Hirschsprung H. Stuhlträchtigkeit neugeborener infolge von dilatation und hypertrophic des colons. *Jb inderheilk* 1888;**27**:1.
- Whitehouse F, Kernohan J. Myenteric plexuses in congenital megacolon; study of 11 cases. *Arch Int Med* 1948;**82**:75.
- Meier-Ruge W, Lutterbeck PM, Herzog B, Morger R, Moser R, Scharli A. Acetylcholinesterase activity in suction biopsies of the rectum in the diagnosis of Hirschsprung's disease. *J Pediatr Surg* 1972;**7**:11–7.
- Swenson O. Early history of the therapy of Hirschsprung's disease: facts and personal observations over 50 years. *J Pediatr Surg* 1996;**31**:1003–8.
- Bodian M, Carter C. A family study of Hirschsprung disease. *Ann Hum Genet* 1963;**26**:261.
- Bolande RP. The neurocristopathies; a unifying concept of disease arising in neural crest maldevelopment. *Hum Pathol* 1974;**5**:409–20.
- Le Douarin N, Kalcheim C. *The neural crest*. 2nd ed. Cambridge: Cambridge University Press, 1999.
- Iwashita T, Kruger GM, Pardal R, Kiel MJ, Morrison SJ. Hirschsprung disease is linked to defects in neural crest stem cell function. *Science* 2003;**301**:972–6.
- Badner JA, Chakravarti A. Waardenburg syndrome and Hirschsprung disease: evidence for pleiotropic effects of a single dominant gene. *Am J Med Genet* 1990;**35**:100–4.
- Passarge E. The genetics of Hirschsprung's disease. Evidence for heterogeneous etiology and a study of sixty-three families. *N Engl J Med* 1967;**276**:138–43.
- Goldberg EL. An epidemiological study of Hirschsprung's disease. *Int J Epidemiol* 1984;**13**:479–85.
- Garver KL, Law JC, Garver B. Hirschsprung disease: a genetic study. *Clin Genet* 1985;**28**:503–8.
- Spouge D, Baird PA. Hirschsprung disease in a large birth cohort. *Teratology* 1985;**32**:171–7.
- Brooks AS, Breuning MH, Meijers C. Spectrum of phenotypes associated with Hirschsprung disease: an evaluation of 239 patients from a single institution. *The Third International Meeting: Hirschsprung disease and related neurocristopathies*. Evian, France, 1998.
- Torfs CP. An epidemiological study of Hirschsprung disease in a multiracial California population. *The Third International Meetings: Hirschsprung disease and related neurocristopathies*. Evian, France, 1998.
- Taraviras S, Pachnis V. Development of the mammalian enteric nervous system. *Curr Opin Genet Dev* 1999;**9**:321.
- Nihoul-Fékété C, Ricour C, Martelli H, Lortat Jacob S, Pellerin D. Total colonic aganglionosis (with or without ileal involvement): a review of 27 cases. *J Pediatr Surg* 1986;**21**:251.
- Neilson IR, Yazbeck S. Ultrashort Hirschsprung's disease: myth or reality. *J Pediatr Surg* 1990;**25**:1135–8.
- Parc R, Berrod JL, Tussiot J, Loygue J. [Megacolon in adults. Apropos of 76 cases]. *Ann Gastroenterol Hepatol (Paris)* 1984;**20**:133–41.
- Emir H, Akman M, Sarimurat N, Kilic N, Erdogan E, Soylet Y. Anorectal manometry during the neonatal period: its specificity in the diagnosis of Hirschsprung's disease. *Eur J Pediatr Surg* 1999;**9**:101–3.
- Lopez Alonso M. [Manometric study in the newborn]. *Cir Pediatr* 1992;**5**:66–71.
- Kurer MH, Lawson JO, Pambakian H. Suction biopsy in Hirschsprung's disease. *Arch Dis Child* 1986;**61**:83–4.
- Soave F. Hirschsprung's disease. Technique and results of Soave's operation. *Br J Surg* 1966;**53**:1023–7.
- Newbern WR. Hirschsprung's disease—the Duhamel modification. *Am J Gastroenterol* 1967;**47**:61–8.
- Albanese CT, Jennings RW, Smith B, Bratton B, Harrison MR. Perineal one-stage pull-through for Hirschsprung's disease. *J Pediatr Surg* 1999;**34**:377–80.
- Langer JC, Durrant AC, de la Torre L, Teitelbaum DH, Minkes RK, Caty MG, Wildhaber BE, Ortega SJ, Hirose S, Albanese CT. One-stage transanal Soave pull-through for Hirschsprung disease: a multicenter experience with 141 children. *Ann Surg* 2003;**238**:569–83; discussion 583–5.
- El-Sawaf MI, Drongowski RA, Chamberlain JN, Coran AG, Teitelbaum DH. Are the long-term results of the transanal pull-through equal to those of the transabdominal pull-through? A comparison of the 2 approaches for Hirschsprung disease. *J Pediatr Surg* 2007;**42**:41–7; discussion 47.
- Rauch U, Hansgen A, Hagl C, Holland-Cunz S, Schafer KH. Isolation and cultivation of neuronal precursor cells from the developing human enteric nervous system as a tool for cell therapy in dysganglionosis. *Int J Colorectal Dis* 2006;**21**:554–9.
- Heanue TA, Pachnis V. Enteric nervous system development and Hirschsprung's disease: advances in genetic and stem cell studies. *Nat Rev Neurosci* 2007;**8**:466–79.
- Hackam DJ, Filler RM, Pearl RH. Enterocolitis after the surgical treatment of Hirschsprung's disease: risk factors and financial impact. *J Pediatr Surg* 1998;**33**:830–3.
- Yanchar NL, Soucy P. Long-term outcome after Hirschsprung's disease: patients' perspectives. *J Pediatr Surg* 1999;**34**:1152–60.

32. **Moore SW**, Albertyn R, Cywes S. Clinical outcome and long-term quality of life after surgical correction of Hirschsprung's disease. *J Pediatr Surg* 1996;**31**:1496–502.
33. **Jasonni V**, Martucciello G. Total colonic aganglionosis. *Semin Pediatr Surg* 1998;**7**:174–80.
34. **Tsuji H**, Spitz L, Kiely EM, Drake DP, Pierro A. Management and long-term follow-up of infants with total colonic aganglionosis. *J Pediatr Surg* 1999;**34**:158–61; discussion 162.
35. **Badner JA**, Sieber WK, Garver KL, Chakravarti A. A genetic study of Hirschsprung disease. *Am J Hum Genet* 1990;**46**:568–80.
36. **Lyonnet S**, Bolino A, Pelet A, Abel L, Nihoul-Fekete C, Briard ML, Mok-Siu V, Kaariainen H, Martucciello G, Lerone M, et al. A gene for Hirschsprung disease maps to the proximal long arm of chromosome 10. *Nat Genet* 1993;**4**:346–50.
37. **Angrist M**, Kauffman E, Slaugenhaupt SA, Matise TC, Puffenberger EG, Washington SS, Lipson A, Cass DT, Reyna T, Weeks DE, et al. A gene for Hirschsprung disease (megacolon) in the pericentromeric region of human chromosome 10. *Nat Genet* 1993;**4**:351–6.
38. **Martucciello G**, Biocchini M, Doderio P, Cirillo M, Puliti A, Gimelli G. Total colonic aganglionosis associated with interstitial deletion of the long arm of chromosome 10. *Pediatr Surg Int* 1992;**7**:308.
39. **Mulligan LM**, Kwok JB, Healey CS, Elsdon MJ, Eng C, Gardner E, Love DR, Mole SE, Moore JK, Papi L. Germ-line mutations of the RET proto-oncogene in multiple endocrine neoplasia type 2A. *Nature* 1993;**363**:458–60.
40. **Donis-Keller H**, Dou S, Chi D, Carlson KM, Toshima K, Lairmore TC, Howe JR, Moley JF, Goodfellow P, Wells SA. Mutations in the RET proto-oncogene are associated with MEN 2A and FMTC. *Hum Mol Genet* 1993;**2**:851–6.
41. **Edery P**, Lyonnet S, Mulligan LM, Pelet A, Dow E, Abel L, Holder S, Nihoul-Fekete C, Ponder BA, Munnich A. Mutations of the RET proto-oncogene in Hirschsprung's disease. *Nature* 1994;**367**:378–80.
42. **Romeo G**, Ronchetto P, Luo Y, Barone V, Seri M, Ceccherini I, Pasini B, Boccardi R, Lerone M, Kaariainen H, et al. Point mutations affecting the tyrosine kinase domain of the RET proto-oncogene in Hirschsprung's disease. *Nature* 1994;**367**:377–8.
43. **Angrist M**, Bolk S, Thiel B, Puffenberger EG, Hofstra RM, Buys CH, Cass DT, Chakravarti A. Mutation analysis of the RET receptor tyrosine kinase in Hirschsprung disease. *Hum Mol Genet* 1995;**4**:821–30.
44. **Attie T**, Pelet A, Edery P, Eng C, Mulligan LM, Amiel J, Boutrand L, Beldjord C, Nihoul-Fekete C, Munnich A, et al. Diversity of RET proto-oncogene mutations in familial and sporadic Hirschsprung disease. *Hum Mol Genet* 1995;**4**:1381–6.
45. **Seri M**, Yin L, Barone V, Bolino A, Celli I, Boccardi R, Pasini B, Ceccherini I, Lerone M, Kristofferson U, Larsson LT, Casasa JM, Cass DT, Abramowicz MJ, Vanderwinden JM, Kravcenkiene I, Baric I, Silengo M, Martucciello G, Romeo G. Frequency of RET mutations in long- and short-segment Hirschsprung disease. *Hum Mutat* 1997;**9**:243–9.
46. **Hofstra RM**, Wu Y, Stulp RP, Elfferich P, Osinga J, Maas SM, Siderius L, Brooks AS, vd Ende JJ, Heydendaal VM, Severijnen RS, Bax KM, Meijers C, Buys CH. RET and GDNF gene scanning in Hirschsprung patients using two dual denaturing gel systems. *Hum Mutat* 2000;**15**:418–29.
47. **Mulligan LM**, Eng C, Attie T, Lyonnet S, Marsh DJ, Hyland VJ, Robinson BG, Frilling A, Verellen-Dumoulin C, Safar A, et al. Diverse phenotypes associated with exon 10 mutations of the RET proto-oncogene. *Hum Mol Genet* 1994;**3**:2163–7.
48. **Eng C**, Smith DP, Mulligan LM, Nagai MA, Healey CS, Ponder MA, Gardner E, Scheumann GF, Jackson CE, Tunnacliffe A, et al. Point mutation within the tyrosine kinase domain of the RET proto-oncogene in multiple endocrine neoplasia type 2B and related sporadic tumours [erratum in *Hum Mol Genet* 1994;**3**:686]. *Hum Mol Genet* 1994;**3**:237–41.
49. **Hofstra RM**, Landsvater RM, Ceccherini I, Stulp R, Stelwagen T, Luo Y, Pasini B, Hoppener JW, van Amstel HKGR. A mutation in the RET proto-oncogene associated with multiple endocrine neoplasia type 2B and sporadic medullary thyroid carcinoma. *Nature* 1994;**367**:375–6.
50. **Carlson KM**, Dou S, Chi D, Scavarda N, Toshima K, Jackson CE, Wells SAJ, Goodfellow PJ, Donis-Keller H. Single missense mutation in the tyrosine kinase catalytic domain of the RET proto-oncogene is associated with multiple endocrine neoplasia type 2B. *Proc Natl Acad Sci U S A* 1994;**91**:1579–83.
51. **Plaza Menacho I**, Koster R, van der Sloot AM, Quax WJ, Osinga J, van der Sluis T, Hollema H, Burzynski GM, Gimm O, Buys CH, Eggen BJ, Hofstra RM. RET-familial medullary thyroid carcinoma mutants Y791F and S891A activate a Src/JAK/STAT3 pathway, independent of glial cell line-derived neurotrophic factor. *Cancer Res* 2005;**65**:1729–37.
52. **Santoro M**, Carlomagno F, Romano A, Bottaro DP, Dathan NA, Grieco M, Fusco A, Vecchio G, Matoskova B, Kraus MH. Activation of RET as a dominant transforming gene by germline mutations of MEN2A and MEN2B. *Science* 1995;**267**:381–3.
53. **Pasini B**, Borrello MG, Greco A, Bongarzone I, Luo Y, Mondellini P, Alberti L, Miranda C, Arighi E, Boccardi R, et al. Loss of function effect of RET mutations causing Hirschsprung disease. *Nat Genet* 1995;**10**:35–40.
54. **Carlomagno F**, De Vita G, Berlingieri MT, de Francis V, Melillo RM, Colantuoni V, Kraus MH, Di Fiore PP, Fusco A, Santoro M. Molecular heterogeneity of RET loss of function in Hirschsprung's disease. *Embo J* 1996;**15**:2717–25.
55. **Iwashita T**, Murakami H, Asai N, Takahashi M. Mechanism of ret dysfunction by Hirschsprung mutations affecting its extracellular domain. *Hum Mol Genet* 1996;**5**:1577–80.
56. **Pelet A**, Geneste O, Edery P, Pasini A, Chappuis S, Atti T, Munnich A, Lenoir G, Lyonnet S, Billaud M. Various mechanisms cause RET-mediated signaling defects in Hirschsprung's disease. *J Clin Invest* 1998;**101**:1415–23.
57. **Iwashita T**, Kurokawa K, Qiao S, Murakami H, Asai N, Kawai K, Hashimoto M, Watanabe T, Ichihara M, Takahashi M. Functional analysis of RET with Hirschsprung mutations affecting its kinase domain. *Gastroenterology* 2001;**121**:24–33.
58. **Manie S**, Santoro M, Fusco A, Billaud M. The RET receptor: function in development and dysfunction in congenital malformation. *Trends Genet* 2001;**17**:580–9.
59. **Lantieri F**, Griseri P, Ceccherini I. Molecular mechanisms of RET-induced Hirschsprung pathogenesis. *Ann Med* 2006;**38**:11–19.
60. **Sancandi M**, Ceccherini I, Costa M, Fava M, Chen B, Wu Y, Hofstra R, Laurie T, Griffiths M, Burge D, Tam PK. Incidence of RET mutations in patients with Hirschsprung's disease. *J Pediatr Surg* 2000;**35**:139–42; discussion 142–3.
61. **Garcia-Barcelo M**, Sham MH, Lee WS, Lui VC, Chen BL, Wong KK, Wong JS, Tam PK. Highly recurrent RET mutations and novel mutations in genes of the receptor tyrosine kinase and endothelin receptor B pathways in Chinese patients with sporadic Hirschsprung disease. *Clin Chem* 2004;**50**:93–100.
62. **Bolk S**, Pelet A, Hofstra RM, Angrist M, Salomon R, Croaker D, Buys CH, Lyonnet S, Chakravarti A. A human model for multigenic inheritance: phenotypic expression in Hirschsprung disease requires both the RET gene and a new 9q31 locus. *Proc Natl Acad Sci U S A* 2000;**97**:268–73.
63. **Fitze G**, Schreiber M, Kuhlisch E, Schackert HK, Roesner D. Association of RET proto-oncogene codon 45 polymorphism with Hirschsprung disease. *Am J Hum Genet* 1999;**65**:1469–73.
64. **Borrego S**, Saez ME, Ruiz A, Gimm O, Lopez-Alonso M, Antinolo G, Eng C. Specific polymorphisms in the RET proto-oncogene are over-represented in patients with Hirschsprung disease and may represent loci modifying phenotypic expression. *J Med Genet* 1999;**36**:771–4.
65. **Borrego S**, Ruiz A, Saez ME, Gimm O, Gao X, Lopez-Alonso M, Hernandez A, Wright FA, Antinolo G, Eng C. RET genotypes comprising specific haplotypes of polymorphic variants predispose to isolated Hirschsprung disease. *J Med Genet* 2000;**37**:572–8.
66. **Garcia-Barcelo M**, Sham MH, Lui VC, Chen BL, Ott J, Tam PK. Association study of PHOX2B as a candidate gene for Hirschsprung's disease. *Gut* 2003;**52**:563–7.
67. **Burzynski GM**, Nolte IM, Osinga J, Ceccherini I, Twigg B, Maas S, Brooks A, Verheij J, Plaza Menacho I, Buys CH, Hofstra RM. Localizing a putative mutation as the major contributor to the development of sporadic Hirschsprung disease to the RET genomic sequence between the promoter region and exon 2. *Eur J Hum Genet* 2004;**12**:604–12.
68. **Pelet A**, de Pontual L, Clement-Ziza M, Salomon R, Mugnier C, Matsuda F, Lathrop M, Munnich A, Feingold J, Lyonnet S, Abel L, Amiel J. Homozygosity for a frequent and weakly penetrant predisposing allele at the RET locus in sporadic Hirschsprung disease. *J Med Genet* 2005;**42**:e18.
69. **Borrego S**, Fernandez RM, Dziema H, Niess A, Lopez-Alonso M, Antinolo G, Eng C. Investigation of germline GFRA4 mutations and evaluation of the involvement of GFRA1, GFRA2, GFRA3, and GFRA4 sequence variants in Hirschsprung disease. *J Med Genet* 2003;**40**:e18.
70. **Sancandi M**, Griseri P, Pesce B, Patrone G, Puppo F, Lerone M, Martucciello G, Romeo G, Ravazzolo R, Devoto M, Ceccherini I. Single nucleotide polymorphic alleles in the 5' region of the RET proto-oncogene define a risk haplotype in Hirschsprung's disease. *J Med Genet* 2003;**40**:714–8.
71. **Garcia-Barcelo M**, Ganster RW, Lui VC, Leon TY, So MT, Lau AM, Fu M, Sham MH, Knight J, Zannini MS, Sham PC, Tam PK. TTF-1 and RET promoter SNPs: regulation of RET transcription in Hirschsprung's disease. *Hum Mol Genet* 2005;**14**:191–204.
72. **Fernandez RM**, Boru G, Pecina A, Jones K, Lopez-Alonso M, Antinolo G, Borrego S, Eng C. Ancestral RET haplotype associated with Hirschsprung's disease shows linkage disequilibrium breakpoint at -1249. *J Med Genet* 2005;**42**:322–7.
73. **Fitze G**, Paditz E, Schlafke M, Kuhlisch E, Roesner D, Schackert HK. Association of germline mutations and polymorphisms of the RET proto-oncogene with idiopathic congenital central hypoventilation syndrome in 33 patients. *J Med Genet* 2003;**40**:E10.
74. **Griseri P**, Bachetti T, Puppo F, Lantieri F, Ravazzolo R, Devoto M, Ceccherini I. A common haplotype at the 5' end of the RET proto-oncogene, overrepresented in Hirschsprung patients, is associated with reduced gene expression. *Hum Mutat* 2005;**25**:189–95.
75. **Emison ES**, McCallion AS, Kashuk CS, Bush RT, Grice E, Lin S, Portnoy ME, Cutler DJ, Green ED, Chakravarti A. A common sex-dependent mutation in a RET enhancer underlies Hirschsprung disease risk. *Nature* 2005;**434**:857–63.
76. **Widlund HR**, Fisher DE. Microphthalmia-associated transcription factor: a critical regulator of pigment cell development and survival. *Oncogene* 2003;**22**:3035–41.
77. **Chattopadhyay P**, Pakstis AJ, Mukherjee N, Iyengar S, Odunsi A, Okonofua F, Bonne-Tamir B, Speed W, Kidd JR, Kidd KK. Global survey of haplotype frequencies and linkage disequilibrium at the RET locus. *Eur J Hum Genet* 2003;**11**:760–9.
78. **Griseri P**, Sancandi M, Patrone G, Boccardi R, Hofstra R, Ravazzolo R, Devoto M, Romeo G, Ceccherini I. A single-nucleotide polymorphic variant of the RET proto-oncogene is underrepresented in sporadic Hirschsprung disease. *Eur J Hum Genet* 2000;**8**:721–4.
79. **Griseri P**, Pesce B, Patrone G, Osinga J, Puppo F, Sancandi M, Hofstra R, Romeo G, Ravazzolo R, Devoto M, Ceccherini I. A rare haplotype of the RET proto-oncogene is a risk-modifying allele in Hirschsprung disease. *Am J Hum Genet* 2002;**71**:969–74.
80. **Griseri P**, Lantieri F, Puppo F, Bachetti T, Di Duca M, Ravazzolo R, Ceccherini I. A common variant located in the 3'UTR of the RET gene is associated with protection from Hirschsprung disease. *Hum Mutat* 2007;**28**:168–76.

81. **Ceccherini I**, Boccardi R, Luo Y, Pasini B, Hofstra R, Takahashi M, Romeo G. Exon structure and flanking intronic sequences of the human RET proto-oncogene. *Biochem Biophys Res Commun* 1993;**196**:1288–95.
82. **Schuchardt A**, D'Agati V, Larsson-Blomberg L, Costantini F, Pachnis V. Defects in the kidney and enteric nervous system of mice lacking the tyrosine kinase receptor Ret. *Nature* 1994;**367**:380–3.
83. **Costantini F**, Shakya R. GDNF/Ret signaling and the development of the kidney. *Bioessays* 2006;**28**:117–27.
84. **Clarke JC**, Patel SR, Raymond RM Jr, Andrew S, Robinson BG, Dressler GR, Brophy PD. Regulation of c-Ret in the developing kidney is responsive to Pax2 gene dosage. *Hum Mol Genet* 2006;**15**:3420–8.
85. **Cao T**, Shannon M, Handel MA, Etkin LD. Mouse ret finger protein (rfp) proto-oncogene is expressed at specific stages of mouse spermatogenesis. *Dev Genet* 1996;**19**:309–20.
86. **Meng X**, Lindahl M, Hyvonen ME, Parvinen M, de Rooij DG, Hess MW, Raatikainen-Ahokas A, Sainio K, Rauvala H, Lakso M, Pichel JG, Westphal H, Saarma M, Sariola H. Regulation of cell fate decision of undifferentiated spermatogonia by GDNF. *Science* 2000;**287**:1489–93.
87. **Jain S**, Naughton CK, Yang M, Strickland A, Vij K, Encinas M, Golden J, Gupta A, Heuckeroth R, Johnson EM Jr, Milbrandt J. Mice expressing a dominant-negative Ret mutation phenocopy human Hirschsprung disease and delineate a direct role of Ret in spermatogenesis. *Development* 2004;**131**:5503–13.
88. **Naughton CK**, Jain S, Strickland AM, Gupta A, Milbrandt J. Glial cell-line derived neurotrophic factor-mediated RET signaling regulates spermatogonial stem cell fate. *Biol Reprod* 2006;**74**:314–21.
89. **Fukuyama S**, Kiyono H. Neuroregulator RET initiates Peyer's-patch tissue genesis. *Immunity* 2007;**26**:393–5.
90. **Veiga-Fernandes H**, Coles MC, Foster KE, Patel A, Williams A, Natarajan D, Barlow A, Pachnis V, Kiousis D. Tyrosine kinase receptor RET is a key regulator of Peyer's patch organogenesis. *Nature* 2007;**446**:547–51.
91. **de Graaff E**, Srinivas S, Kilkenny C, D'Agati V, Mankoo BS, Costantini F, Pachnis V. Differential activities of the RET tyrosine kinase receptor isoforms during mammalian embryogenesis. *Genes Dev* 2001;**15**:2433–44.
92. **Moore MW**, Klein RD, Farinas I, Sauer H, Armanini M, Phillips H, Reichardt LF, Ryan AM, Carver-Moore K, Rosenthal A. Renal and neuronal abnormalities in mice lacking GDNF. *Nature* 1996;**382**:76–9.
93. **Sanchez MP**, Silos-Santiago I, Frisen J, He B, Lira SA, Barbacid M. Renal agenesis and the absence of enteric neurons in mice lacking GDNF. *Nature* 1996;**382**:70–3.
94. **Pichel JG**, Shen L, Sheng HZ, Granholm AC, Drago J, Grinberg A, Lee EJ, Huang SP, Saarma M, Hoffer BJ, Sariola H, Westphal H. Defects in enteric innervation and kidney development in mice lacking GDNF. *Nature* 1996;**382**:73–6.
95. **Durbec P**, Marcos-Gutierrez CV, Kilkenny C, Grigoriou M, Wartiovaara K, Suvanto P, Smith D, Ponder B, Costantini F, Saarma M, et al. GDNF signalling through the Ret receptor tyrosine kinase. *Nature* 1996;**381**:789–93.
96. **Jing S**, Wen D, Yu Y, Holst PL, Luo Y, Fang M, Tamir R, Antonio L, Hu Z, Cupples R, Louis JC, Hu S, Altmann BW, Fox GM. GDNF-induced activation of the ret protein tyrosine kinase is mediated by GDNFR-alpha, a novel receptor for GDNF. *Cell* 1996;**85**:1113–24.
97. **Treanor JJ**, Goodman L, de Sauvage F, Stone DM, Poulsen KT, Beck CD, Gray C, Armanini MP, Pollock RA, Hefti F, Phillips HS, Goddard A, Moore MW, Buj-Bello A, Davies AM, Asai N, Takahashi M, Vanden R, Henderson CE, Rosenthal A. Characterization of a multicomponent receptor for GDNF. *Nature* 1996;**382**:80–3.
98. **Rosenthal A**. The GDNF protein family: gene ablation studies reveal what they really do and how. *Neuron* 1999;**22**:201–3.
99. **Kotzbauer PT**, Lampe PA, Heuckeroth RO, Golden JP, Creighton DJ, Johnson EM, Milbrandt J. Neurturin, a relative of glial-cell-line-derived neurotrophic factor. *Nature* 1996;**384**:467–70.
100. **Milbrandt J**, de Sauvage FJ, Fahrner TJ, Baloh RH, Leitner ML, Tansey MG, Lampe PA, Heuckeroth RO, Kotzbauer PT, Simburger KS, Golden JP, Davies JA, Vejtsada R, Kato AC, Hynes M, Sherman D, Nishimura M, Wang LC, Vanden R, Moffat B, Klein RD, Poulsen K, Gray C, Garcias A, Johnson EM, et al. Persephin, a novel neurotrophic factor related to GDNF and neurturin. *Neuron* 1998;**20**:245–53.
101. **Baloh RH**, Tansey MG, Lampe PA, Fahrner TJ, Enomoto H, Simburger KS, Leitner ML, Araki T, Johnson EM, Milbrandt J. Artemin, a novel member of the GDNF ligand family, supports peripheral and central neurons and signals through the GFRalpha3-RET receptor complex. *Neuron* 1998;**21**:1291–302.
102. **Angrist M**, Bolk S, Halushka M, Lapchak PA, Chakravarti A. Germline mutations in glial cell line-derived neurotrophic factor (GDNF) and RET in a Hirschsprung disease patient. *Nat Genet* 1996;**14**:341–4.
103. **Salomon R**, Attie T, Pelet A, Bidaud C, Eng C, Amiel J, Sarnacki S, Goulet O, Ricour C, Nihoul-Fekete C, Munnich A, Lyonnet S. Germline mutations of the RET ligand GDNF are not sufficient to cause Hirschsprung disease. *Nat Genet* 1996;**14**:345–7.
104. **Ivanchuk SM**, Myers SM, Eng C, Mulligan LM. De novo mutation of GDNF, ligand for the RET/GDNFR-alpha receptor complex, in Hirschsprung disease. *Hum Mol Genet* 1996;**5**:2023–6.
105. **Doray B**, Salomon R, Amiel J, Pelet A, Touraine R, Billaud M, Attie T, Bachy B, Munnich A, Lyonnet S. Mutation of the RET ligand, neurturin, supports multigenic inheritance in Hirschsprung disease [erratum in *Hum Mol Genet* 1998;**7**:1831]. *Hum Mol Genet* 1998;**7**:1449–52.
106. **Cacalano G**, Farinas I, Wang LC, Hagler K, Forgie A, Moore M, Armanini M, Phillips H, Ryan AM, Reichardt LF, Hynes M, Davies A, Rosenthal A. GFRalpha1 is an essential receptor component for GDNF in the developing nervous system and kidney. *Neuron* 1998;**21**:53–62.
107. **Enomoto H**, Araki T, Jackman A, Heuckeroth RO, Snider WD, Johnson EM, Milbrandt J. GFR alpha1-deficient mice have deficits in the enteric nervous system and kidneys. *Neuron* 1998;**21**:317–24.
108. **Angrist M**, Jing S, Bolk S, Bentley K, Nallasamy S, Halushka M, Fox GM, Chakravarti A. Human GFRA1: cloning, mapping, genomic structure, and evaluation as a candidate gene for Hirschsprung disease susceptibility. *Genomics* 1998;**48**:354–62.
109. **Myers SM**, Salomon R, Goessling A, Pelet A, Eng C, von Deimling A, Lyonnet S, Mulligan LM. Investigation of germline GFR alpha-1 mutations in Hirschsprung disease. *J Med Genet* 1999;**36**:217–20.
110. **Bordeaux MC**, Forcet C, Granger L, Corset V, Bidaud C, Billaud M, Bredesen DE, Edery P, Mehlen P. The RET proto-oncogene induces apoptosis: a novel mechanism for Hirschsprung disease. *Embo J* 2000;**19**:4056–63.
111. **Inoue A**, Yanagisawa M, Kimura S, Kasuya Y, Miyauchi T, Goto K, Masaki T. The human endothelin family: three structurally and pharmacologically distinct isopeptides predicted by three separate genes. *Proc Natl Acad Sci U S A* 1989;**86**:2863–7.
112. **Sakurai T**, Yanagisawa M, Masaki T. Molecular characterization of endothelin receptors. *Trends Pharmacol Sci* 1992;**13**:103–8.
113. **Cohen IT**, Gadd MA. Hirschsprung's disease in a kindred: a possible clue to the genetics of the disease. *J Pediatr Surg* 1982;**17**:632–4.
114. **Puffenberger EG**, Kauffman ER, Bolk S, Matise TC, Washington SS, Angrist M, Weissbach J, Garver KL, Mascari M, Ladda R, et al. Identity-by-descent and association mapping of a recessive gene for Hirschsprung disease on human chromosome 13q22. *Hum Mol Genet* 1994;**3**:1217–25.
115. **Van Camp G**, Van Thienen MN, Handig I, Van Roy B, Rao VS, Milunsky A, Read AP, Baldwin CT, Farrer LA, Bonduelle M, et al. Chromosome 13q deletion with Waardenburg syndrome: further evidence for a gene involved in neural crest function on 13q. *J Med Genet* 1995;**32**:531–6.
116. **Shanske A**, Ferreira JC, Leonard JC, Fuller P, Marion RW. Hirschsprung disease in an infant with a contiguous gene syndrome of chromosome 13. *Am J Med Genet* 2001;**102**:231–6.
117. **Hosoda K**, Hammer RE, Richardson JA, Baynash AG, Cheung JC, Gaiad A, Yanagisawa M. Targeted and natural (piebald-lethal) mutations of endothelin-B receptor gene produce megacolon associated with spotted coat color in mice. *Cell* 1994;**79**:1267–76.
118. **Puffenberger EG**, Hosoda K, Washington SS, Nakao K, deWit D, Yanagisawa M, Chakravarti A. A missense mutation of the endothelin-B receptor gene in multigenic Hirschsprung's disease. *Cell* 1994;**79**:1257–66.
119. **Baynash AG**, Hosoda K, Gaiad A, Richardson JA, Emoto N, Hammer RE, Yanagisawa M. Interaction of endothelin-3 with endothelin-B receptor is essential for development of epidermal melanocytes and enteric neurons. *Cell* 1994;**79**:1277–85.
120. **Hofstra RM**, Osinga J, Tan-Sindhunata G, Wu Y, Kamsteeg EJ, Stulp RP, van Ravenswaaij-Arts C, Majoor-Krakauer D, Angrist M, Chakravarti A, Meijers C, Buys CH. A homozygous mutation in the endothelin-3 gene associated with a combined Waardenburg type 2 and Hirschsprung phenotype (Shah-Waardenburg syndrome). *Nat Genet* 1996;**12**:445–7.
121. **Edery P**, Attie T, Amiel J, Pelet A, Eng C, Hofstra RM, Martelli H, Bidaud C, Munnich A, Lyonnet S. Mutation of the endothelin-3 gene in the Waardenburg-Hirschsprung disease (Shah-Waardenburg syndrome). *Nat Genet* 1996;**12**:442–4.
122. **Pingault V**, Bondurand N, Kuhlbrodt K, Goerich DE, Prehu MO, Puliti A, Herbarth B, Hermans-Borgmeyer I, Legius E, Matthijs G, Amiel J, Lyonnet S, Ceccherini I, Romeo G, Smith JC, Read AP, Wegner M, Goossens M. SOX10 mutations in patients with Waardenburg-Hirschsprung disease. *Nat Genet* 1998;**18**:171–3.
123. **Touraine RL**, Attie-Bitach T, Manceau E, Korsch E, Sarda P, Pingault V, Encha-Razavi F, Pelet A, Auge J, Nivelon-Chevallier A, Holschneider AM, Munnes M, Doerfler W, Goossens M, Munnich A, Vekemans M, Lyonnet S. Neurological phenotype in Waardenburg syndrome type 4 correlates with novel SOX10 truncating mutations and expression in developing brain. *Am J Hum Genet* 2000;**66**:1496–503.
124. **Southard-Smith EM**, Angrist M, Ellison JS, Agarwala R, Baxevaris AD, Chakravarti A, Pavan WJ. The Sox10(Dom) mouse: modeling the genetic variation of Waardenburg-Shah (WS4) syndrome. *Genome Res* 1999;**9**:215–25.
125. **Herbarth B**, Pingault V, Bondurand N, Kuhlbrodt K, Hermans-Borgmeyer I, Puliti A, Lemont N, Goossens M, Wegner M. Mutation of the Sry-related Sox10 gene in dominant megacolon, a mouse model for human Hirschsprung disease. *Proc Natl Acad Sci U S A* 1998;**95**:5161–5.
126. **Chakravarti A**. Endothelin receptor-mediated signaling in Hirschsprung disease. *Hum Mol Genet* 1996;**5**:303–7.
127. **Amiel J**, Attie T, Jan D, Pelet A, Edery P, Bidaud C, Lacombe D, Tam P, Simeoni J, Flori E, Nihoul-Fekete C, Munnich A, Lyonnet S. Heterozygous endothelin receptor B (EDNRB) mutations in isolated Hirschsprung disease. *Hum Mol Genet* 1996;**5**:355–7.
128. **Kusafuka T**, Wang Y, Puri P. Novel mutations of the endothelin-B receptor gene in isolated patients with Hirschsprung's disease. *Hum Mol Genet* 1996;**5**:347–9.
129. **Auricchio A**, Casari G, Staiano A, Ballabio A. Endothelin-B receptor mutations in patients with isolated Hirschsprung disease from a non-inbred population. *Hum Mol Genet* 1996;**5**:351–4.
130. **Bidaud C**, Salomon R, Van Camp G, Pelet A, Attie T, Eng C, Bonduelle M, Amiel J, Nihoul-Fekete C, Willems PJ, Munnich A, Lyonnet S. Endothelin-3 gene mutations in isolated and syndromic Hirschsprung disease. *Eur J Hum Genet* 1997;**5**:247–51.
131. **Hofstra RM**, Valdenaire O, Arch E, Osinga J, Kroes H, Löffler BM, Hamosh A, Meijers C, Buys CH. A loss-of-function mutation in the endothelin-converting enzyme

- 1 (ECE-1) associated with Hirschsprung disease, cardiac defects, and autonomic dysfunction. *Am J Hum Genet* 1999;**64**:304–8.
132. **Yanagisawa H**, Yanagisawa M, Kapur RP, Richardson JA, Williams SC, Clouthier DE, de Wit D, Emoto N, Hammer RE. Dual genetic pathways of endothelin-mediated intercellular signaling revealed by targeted disruption of endothelin converting enzyme-1 gene. *Development* 1998;**125**:825–36.
133. **Lurie IW**, Supovitz KR, Rosenblum-Vos LS, Wulfsberg EA. Phenotypic variability of del(2) (q22-q23): report of a case with a review of the literature. *Genet Couns* 1994;**5**:11–4.
134. **Mowat DR**, Croaker GD, Cass DT, Kerr BA, Chaitow J, Ades LC, Chia NL, Wilson MJ. Hirschsprung disease, microcephaly, mental retardation, and characteristic facial features: delineation of a new syndrome and identification of a locus at chromosome 2q22-q23. *J Med Genet* 1998;**35**:617–23.
135. **Wakamatsu N**, Yamada Y, Yamada K, Ono T, Nomura N, Taniguchi H, Kitoh H, Mutoh N, Yamanaka T, Mushiaki K, Kato K, Sonta S, Nagaya M. Mutations in SIP1, encoding Smad interacting protein-1, cause a form of Hirschsprung disease. *Nat Genet* 2001;**27**:369–70.
136. **Van de Putte T**, Maruhashi M, Francis A, Nelles L, Kondoh H, Huylebroeck D, Higashi Y. Mice lacking ZFHX1B, the gene that codes for Smad-interacting protein-1, reveal a role for multiple neural crest cell defects in the etiology of Hirschsprung disease-mental retardation syndrome. *Am J Hum Genet* 2003;**72**:465–70.
137. **Trochet D**, O'Brien LM, Gozal D, Trang H, Nordenskjold A, Laudier B, Svensson PJ, Uhrig S, Cole T, Munnich A, Gaultier C, Lyonnet S, Amiel J. PHOX2B genotype allows for prediction of tumor risk in congenital central hypoventilation syndrome. *Am J Hum Genet* 2005;**76**:421–6.
138. **Trang H**, Dehan M, Beaufils F, Zaccaria I, Amiel J, Gaultier C. The French Congenital Central Hypoventilation Syndrome Registry: general data, phenotype, and genotype. *Chest* 2005;**127**:72–9.
139. **Pattyn A**, Morin X, Cremer H, Goridis C, Brunet JF. The homeobox gene Phox2b is essential for the development of autonomic neural crest derivatives. *Nature* 1999;**399**:366–70.
140. **Dauger S**, Pattyn A, Lofaso F, Gaultier C, Goridis C, Gallego J, Brunet JF. Phox2b controls the development of peripheral chemoreceptors and afferent visceral pathways. *Development* 2003;**130**:6635–42.
141. **Peippo MM**, Simola KO, Valanne LK, Larsen AT, Kahkonen M, Auranen MP, Ignatius J. Pitt-Hopkins syndrome in two patients and further definition of the phenotype. *Clin Dysmorphol* 2006;**15**:47–54.
142. **Amiel J**, Rio M, de Pontual L, Redon R, Malan V, Boddaert N, Plouin P, Carter NP, Lyonnet S, Munnich A, Colleaux L. Mutations in TCF4, encoding a class I basic helix-loop-helix transcription factor, are responsible for Pitt-Hopkins syndrome, a severe epileptic encephalopathy associated with autonomic dysfunction. *Am J Hum Genet* 2007;**80**:988–93.
143. **Zweier C**, Peippo MM, Hoyer J, Sousa S, Bottani A, Clayton-Smith J, Reardon W, Saraiva J, Cabral A, Gohring I, Devriendt K, de Ravel T, Bijlsma EK, Hennekam RC, Orrico A, Cohen M, Dreweke A, Reis A, Nurnberg P, Rauch A. Haploinsufficiency of TCF4 causes syndromal mental retardation with intermittent hyperventilation (Pitt-Hopkins syndrome). *Am J Hum Genet* 2007;**80**:994–1001.
144. **Wang G**, Zhang SH, Lin HJ, Tong EC, Huang YH, Huang GT, Zhuang FT. Nonoperative treatment of Hirschsprung's disease: a new approach. *J Pediatr Surg* 1987;**22**:439–42.
145. **Bergqvist I**, Eriksson M, Saarikettu J, Eriksson B, Corneliussen B, Grundstrom T, Holmberg D. The basic helix-loop-helix transcription factor E2-2 is involved in T lymphocyte development. *Eur J Immunol* 2000;**30**:2857–63.
146. **Fewtrell MS**, Tam PK, Thomson AH, Fitchett M, Currie J, Huson SM, Mulligan LM. Hirschsprung's disease associated with a deletion of chromosome 10 (q11.2q21.2): a further link with the neurocristopathies? *J Med Genet* 1994;**31**:325–7.
147. **McMillin KD**, Reiss JA, Brown MG, Black MH, Buckmaster DA, Durum CT, Gunter KA, Lawce HJ, Berry TL, Lamb OA, Olson CL, Weeks FF, Yoshitomi MJ, Jacky PB, Olson SB, Magenis RE. Clinical outcomes of four patients with microdeletion in the long arm of chromosome 2. *Am J Med Genet* 1998;**78**:36–43.
148. **de Pontual L**, Pelet A, Clement-Ziza M, Trochet D, Antonarakis SE, Attie-Bitach T, Beales PL, Blouin JL, Dastot-Le Moal F, Dollfus H, Goossens M, Katsanis N, Touraine R, Feingold J, Munnich A, Lyonnet S, Amiel J. Epistatic interactions with a common hypomorphic RET allele in syndromic Hirschsprung disease. *Hum Mutat* 2007;**28**:790–796.
149. **Brewer C**, Holloway S, Zawalnyski P, Schinzel A, FitzPatrick D. A chromosomal deletion map of human malformations. *Am J Hum Genet* 1998;**63**:1153–9.
150. **Brewer C**, Holloway S, Zawalnyski P, Schinzel A, FitzPatrick D. A chromosomal duplication map of malformations: regions of suspected haplo- and triplolethality and tolerance of segmental aneuploidy-in humans. *Am J Hum Genet* 1999;**64**:1702–8.
151. **Mahboubi S**, Templeton JM Jr. Association of Hirschsprung's disease and imperforate anus in a patient with "cat-eye" syndrome. A report of one case and review of the literature. *Pediatr Radiol* 1984;**14**:441–2.
152. **Lane PW**, Liu HM. Association of megalocolon with a new dominant spotting gene (Dom) in the mouse. *J Hered* 1984;**75**:435–9.
153. **Bondurand N**, Kuhlbrodt K, Pingault V, Enderich J, Sajus M, Tommerup N, Warburg M, Hennekam RC, Read AP, Wegner M, Goossens M. A molecular analysis of the yemenite deaf-blind hypopigmentation syndrome: SOX10 dysfunction causes different neurocristopathies. *Hum Mol Genet* 1999;**8**:1785–9.
154. **Inoue K**, Khajavi M, Ohyama T, Hirabayashi S, Wilson J, Reggin JD, Mancias P, Butler IJ, Wilkinson MF, Wegner M, Lupski JR. Molecular mechanism for distinct neurological phenotypes conveyed by allelic truncating mutations. *Nat Genet* 2004;**36**:361–9.
155. **Auricchio A**, Griseri P, Carpentieri ML, Betsos N, Staiano A, Tozzi A, Priolo M, Thompson H, Bocciaardi R, Romeo G, Ballabio A, Ceccherini I. Double heterozygosity for a RET substitution interfering with splicing and an EDNRB missense mutation in Hirschsprung disease. *Am J Hum Genet* 1999;**64**:1216–21.
156. **Carrasquillo MM**, McCallion AS, Puffenberger EG, Kashuk CS, Nouri N, Chakravarti A. Genome-wide association study in Mennonites identifies multiple genes for oligogenic Hirschsprung disease. *Am J Hum Genet* 2002;**71**:193.
157. **Potterf SB**, Furumura M, Dunn KJ, Arnheiter H, Pavan WJ. Transcription factor hierarchy in Waardenburg syndrome: regulation of MITF expression by SOX10 and PAX3. *Hum Genet* 2000;**107**:1–6.
158. **Southard-Smith EM**, Kos L, Pavan WJ. Sox10 mutation disrupts neural crest development in Dom Hirschsprung mouse model. *Nat Genet* 1998;**18**:60–4.
159. **Stanchina L**, Baral V, Robert F, Pingault V, Lemont N, Pachnis V, Goossens M, Bondurand N. Interactions between Sox10, Edn3 and Ednrb during enteric nervous system and melanocyte development. *Dev Biol* 2006;**295**:232–49.
160. **Owens SE**, Broman KW, Wiltshire T, Elmore JB, Bradley KM, Smith JR, Southard-Smith EM. Genome-wide linkage identifies novel modifier loci of aganglionosis in the Sox10Dom model of Hirschsprung disease. *Hum Mol Genet* 2005;**14**:1549–58.
161. **Gabriel SB**, Salomon R, Pelet A, Angrist M, Amiel J, Fornage M, Attie-Bitach T, Olson JM, Hofstra R, Buys C, Steffann J, Munnich A, Lyonnet S, Chakravarti A. Segregation at three loci explains familial and population risk in Hirschsprung disease. *Nat Genet* 2002;**31**:89–93.
162. **Brooks AS**, Leegwater PA, Burzynski GM, Willems PJ, de Graaf B, van Langen I, Heutink P, Oostra BA, Hofstra RM, Bertoli-Avella AM. A novel susceptibility locus for Hirschsprung's disease maps to 4q31.3-q32.3. *J Med Genet* 2006;**43**:e35.
163. **Sakai T**, Wakizaka A, Nirasawa Y, Ito Y. Point nucleotide changes in both the RET proto-oncogene and the endothelin-B receptor gene in a Hirschsprung disease patient associated with Down syndrome. *Tohoku J Exp Med* 1999;**187**:43–7.
164. **Sparkes RS**, Sparkes MC, Kalina RE, Pagon RA, Salk DJ, Distech CM. Separation of retinoblastoma and esterase D loci in a patient with sporadic retinoblastoma and del(13)(q14.1q22.3). *Hum Genet* 1984;**68**:258–9.
165. **Lamont MA**, Fitchett M, Dennis NR. Interstitial deletion of distal 13q associated with Hirschsprung's disease. *J Med Genet* 1989;**26**:100–4.
166. **Bottani A**, Xie YG, Binkert F, Schinzel A. A case of Hirschsprung disease with a chromosome 13 microdeletion, del(13)(q32.3q33.2): potential mapping of one disease locus. *Hum Genet* 1991;**87**:748–50.
167. **Benailly H**, Lapiere J, Laudier B, Amiel J, Attie T, De Blois M, Vekemans M, Romana S. PMX2B, a new candidate gene for Hirschsprung's disease. *Clin Genet* 2003;**64**:204–9.
168. **Attie T**, Till M, Pelet A, Amiel J, Edery P, Boutrand L, Munnich A, Lyonnet S. Mutation of the endothelin-receptor B gene in Waardenburg-Hirschsprung disease. *Hum Mol Genet* 1995;**4**:2407–9.
169. **Gross A**, Kunze J, Maier RF, Stoltzenburg-Didinger G, Grimmer I, Obladen M. Autosomal-recessive neural crest syndrome with albinism, black lock, cell migration disorder of the neurocytes of the gut, and deafness: ABCD syndrome. *Am J Med Genet* 1995;**56**:322–6.
170. **Mahakrishnan A**, Srinivasan MS. Piebaldness with Hirschsprung's disease. *Arch Dermatol* 1980;**116**:1102.
171. **Kaplan P**, de Chadrevian JP. Piebaldism-Waardenburg syndrome: histopathologic evidence for a neural crest syndrome. *Am J Med Genet* 1988;**31**:679–88.
172. **Haddad GG**, Mazza NM, Defendini R, Blanc WA, Driscoll JM, Epstein MA, Epstein RA, Mellins RB. Congenital failure of automatic control of ventilation, gastrointestinal motility and heart rate. *Medicine (Baltimore)* 1978;**57**:517–26.
173. **Verloes A**, Elmer C, Lacombe D, Heinrichs C, Rebuffat E, Demarquez JL, Moncla A, Adam E. Ondine-Hirschsprung syndrome (Haddad syndrome). Further delineation in two cases and review of the literature. *Eur J Pediatr* 1993;**152**:75–7.
174. **Amiel J**, Laudier B, Attie-Bitach T, Trang H, de Pontual L, Genser B, Trochet D, Etchevers H, Ray P, Simonneau M, Vekemans M, Munnich A, Gaultier C, Lyonnet S. Polyalanine expansion and frameshift mutations of the paired-like homeobox gene PHOX2B in congenital central hypoventilation syndrome. *Nat Genet* 2003;**33**:459–61.
175. **Verdy M**, Weber AM, Roy CC, Morin CL, Cadotte M, Brochu P. Hirschsprung's disease in a family with multiple endocrine neoplasia type 2. *J Pediatr Gastroenterol Nutr* 1982;**1**:603–7.
176. **Borst MJ**, VanCamp JM, Peacock ML, Decker RA. Mutational analysis of multiple endocrine neoplasia type 2A associated with Hirschsprung's disease. *Surgery* 1995;**117**:386–91.
177. **Caron P**, Attie T, David D, Amiel J, Brousset F, Roger P, Munnich A, Lyonnet S. C618R mutation in exon 10 of the RET proto-oncogene in a kindred with multiple endocrine neoplasia type 2A and Hirschsprung's disease. *J Clin Endocrinol Metab* 1996;**81**:2731–3.
178. **Peretz H**, Luboshitsky R, Baron E, Biton A, Gershoni R, Usher S, Grynberg E, Yakobson E, Graff E, Lapidot M. Cys 618 Arg mutation in the RET proto-oncogene associated with familial medullary thyroid carcinoma and maternally transmitted Hirschsprung's disease suggesting a role for imprinting. *Hum Mutat* 1997;**10**:155–9.
179. **Decker RA**, Peacock ML, Watson P. Hirschsprung disease in MEN 2A: increased spectrum of RET exon 10 genotypes and strong genotype-phenotype correlation. *Hum Mol Genet* 1998;**7**:129–34.
180. **Romeo G**, Ceccherini I, Celli J, Priolo M, Betsos N, Bonardi G, Seri M, Yin L, Lerone M, Jasonni V, Martucciello G. Association of multiple endocrine neoplasia type 2 and Hirschsprung disease. *J Intern Med* 1998;**243**:515–20.

181. **Borrego S**, Eng C, Sanchez B, Saez ME, Navarro E, Antinolo G. Molecular analysis of the ret and GDNF genes in a family with multiple endocrine neoplasia type 2A and Hirschsprung disease. *J Clin Endocrinol Metab* 1998;**83**:3361–4.
182. **Goldberg RB**, Shprintzen RJ. Hirschsprung megacolon and cleft palate in two sibs. *J Craniofac Genet Dev Biol* 1981;**1**:185–9.
183. **Brooks AS**, Breuning MH, Osinga J, vd Smagt JJ, Catsman CE, Buys CH, Meijers C, Hofstra RM. A consanguineous family with Hirschsprung disease, microcephaly, and mental retardation (Goldberg-Shprintzen syndrome). *J Med Genet* 1999;**36**:485–9.
184. **Brooks AS**, Bertoli-Avella AM, Burzynski GM, Breedveld GJ, Osinga J, Boven LG, Hurst JA, Mancini GM, Lequin MH, de Coo RF, Matera I, de Graaff E, Meijers C, Willems PJ, Tibboel D, Oostra BA, Hofstra RM. Homozygous nonsense mutations in KIAA1279 are associated with malformations of the central and enteric nervous systems. *Am J Hum Genet* 2005;**77**:120–6.
185. **Santos H**, Mateus J, Leal MJ. Hirschsprung disease associated with polydactyly, unilateral renal agenesis, hypertelorism, and congenital deafness: a new autosomal recessive syndrome. *J Med Genet* 1988;**25**:204–5.
186. **Laurence KM**, Prosser R, Rocker I, Pearson JF, Richard C. Hirschsprung's disease associated with congenital heart malformation, broad big toes, and ulnar polydactyly in sibs: a case for fetoscopy. *J Med Genet* 1975;**12**:334–8.
187. **al-Gazali LI**, Donnai D, Mueller RF. Hirschsprung's disease, hypoplastic nails, and minor dysmorphic features: a distinct autosomal recessive syndrome? *J Med Genet* 1988;**25**:758–61.
188. **Huang T**, Elias ER, Mulliken JB, Kirse DJ, Holmes LB. A new syndrome: Heart defect, laryngeal anomalies, preaxial polydactyly, and colonic aganglionosis in sibs. *Genet Med* 1999;**1**:104.
189. **Reynolds JF**, Barber JC, Alford BA, Chandler JG, Kelly TE. Familial Hirschsprung's disease and type D brachydactyly: a report of four affected males in two generations. *Pediatrics* 1983;**71**:246–9.
190. **Toriello HV**, Komar K, Lawrence C, Higgins JV, Waterman DF. Macrocephaly, Hirschsprung disease, brachydactyly, vertebral defects, and other minor anomalies. *Dysmorphology and Clinical Genetics* 1988;**1**:155–7.
191. **Cacheux V**, Dastot-Le Moal F, Kaariainen H, Bondurand N, Rintala R, Boissier B, Wilson M, Mowat D, Goossens M. Loss-of-function mutations in SIP1 Smad interacting protein 1 result in a syndromic Hirschsprung disease. *Hum Mol Genet* 2001;**10**:1503–10.
192. **Amiel J**, Espinosa-Parrilla Y, Steffann J, Gosset P, Pelet A, Prieur M, Boute O, Choiset A, Lacombe D, Philip N, Le Merrer M, Tanaka H, Till M, Touraine R, Toutain A, Vekemans M, Munnich A, Lyonnet S. Large-scale deletions and SMADIP1 truncating mutations in syndromic Hirschsprung disease with involvement of midline structures. *Am J Hum Genet* 2001;**69**:1370–7.
193. **Zweier C**, Thiel CT, Dufke A, Crow YJ, Meinecke P, Suri M, Ala-Mello S, Beemer F, Bernasconi S, Bianchi P, Bier A, Devriendt K, Dimitrov B, Firth H, Gallagher RC, Garavelli L, Gillissen-Kaesbach G, Hudgins L, Kaariainen H, Karstens S, Krantz I, Mannhardt A, Medne L, Mucke J, Kibæk M, Krogh LN, Peippo M, Rittinger O, Schulz S, Schelley SL, Temple IK, Dennis NR, Van der Knaap MS, Wheeler P, Yerushalmi B, Zenker M, Seidel H, Lachmeijer A, Prescott T, Kraus C, Lowry RB, Rauch A. Clinical and mutational spectrum of Mowat-Wilson syndrome. *Eur J Med Genet* 2005;**48**:97–111.
194. **Radetti G**, Frick R, Pasquino B, Mengarda G, Savage MO. Hypothalamic-pituitary dysfunction and Hirschsprung's disease in the Bardet-Biedl syndrome. *Helv Paediatr Acta* 1988;**43**:249–52.
195. **Lorda-Sanchez I**, Ayuso C, Ibanez A. Situs inversus and Hirschsprung disease: two uncommon manifestations in Bardet-Biedl syndrome. *Am J Med Genet* 2000;**90**:80–1.
196. **Davenport M**, Taitz LS, Dickson JA. The Kaufman-McKusick syndrome: another association. *J Pediatr Surg* 1989;**24**:1192–4.
197. **Patterson K**, Toomey KE, Chandra RS. Hirschsprung disease in a 46,XY phenotypic infant girl with Smith-Lemli-Opitz syndrome. *J Pediatr* 1983;**103**:425–7.
198. **Makitie O**. [Cartilage-hair hypoplasia—a Finnish growth disorder]. *Duodecim* 1993;**109**:1638–46.
199. **Okamoto N**, Del Maestro R, Valero R, Monros E, Poo P, Kanemura Y, Yamasaki M. Hydrocephalus and Hirschsprung's disease with a mutation of L1CAM. *J Hum Genet* 2004;**49**:334–7.
200. **Mandel H**, Brik R, Ludatscher R, Braun J, Berant M. Congenital muscular dystrophy with neurological abnormalities: association with Hirschsprung disease. *Am J Med Genet* 1993;**47**:37–40.
201. **Kim JJ**, Armstrong DD, Fishman MA. Multicore myopathy, microcephaly, aganglionosis, and short stature. *J Child Neurol* 1994;**9**:275–7.
202. **Mallory SB**, Haynie LS, Williams ML, Hall W. Ichthyosis, deafness, and Hirschsprung's disease. *Pediatr Dermatol* 1989;**6**:24–7.
203. **Kaplan P**. X linked recessive inheritance of agenesis of the corpus callosum. *J Med Genet* 1983;**20**:122–4.
204. **Okamoto N**, Wada Y, Goto M. Hydrocephalus and Hirschsprung's disease in a patient with a mutation of L1CAM. *J Med Genet* 1997;**34**:670–1.
205. **Hall CM**. Werner's mesomelic dysplasia with ventricular septal defect and Hirschsprung's disease. *Pediatr Radiol* 1981;**10**:247–9.
206. **Goldenberg A**, Milh M, de Lagausie P, Mesnage R, Benarif F, de Blois MC, Munnich A, Lyonnet S, Cormier-Daire V. Werner mesomelic dysplasia with Hirschsprung disease. *Am J Med Genet A* 2003;**123**:186–9.
207. **Aurora P**, Wallis CE. Jeune syndrome (asphyxiating thoracic dystrophy) associated with Hirschsprung disease. *Clin Dysmorphol* 1999;**8**:259–63.
208. **Hansford JR**, Mulligan LM. Multiple endocrine neoplasia type 2 and RET: from neoplasia to neurogenesis. *J Med Genet* 2000;**37**:817–27.
209. **Chatten J**, Voorhess ML. Familial neuroblastoma. Report of a kindred with multiple disorders, including neuroblastomas in four siblings. *N Engl J Med* 1967;**277**:1230–6.
210. **Clausen N**, Andersson P, Tommerup N. Familial occurrence of neuroblastoma, von Recklinghausen's neurofibromatosis, Hirschsprung's aganglionosis and jaw-winking syndrome. *Acta Paediatr Scand* 1989;**78**:736–41.
211. **Knudson AG Jr**, Meadows AT. Developmental genetics of neuroblastoma. *J Natl Cancer Inst* 1976;**57**:675–82.
212. **Rohrer T**, Trachsel D, Engelcke G, Hammer J. Congenital central hypoventilation syndrome associated with Hirschsprung's disease and neuroblastoma: case of multiple neurocristopathies. *Pediatr Pulmonol* 2002;**33**:71–6.
213. **Trochet D**, Bourdeaut F, Janoueix-Lerosey I, Deville A, de Pontual L, Schleiermacher G, Coze C, Philip N, Frebourg T, Munnich A, Lyonnet S, Delattre O, Amiel J. Germline mutations of the paired-like homeobox 2B (PHOX2B) gene in neuroblastoma. *Am J Hum Genet* 2004;**74**:761–4.
214. **Mosse YP**, Laudenslager M, Khazi D, Carlisle AJ, Winter CL, Rappaport E, Maris JM. Germline PHOX2B mutation in hereditary neuroblastoma. *Am J Hum Genet* 2004;**75**:727–30.
215. **van Limpt V**, Schramm A, van Lakeman A, Sluis P, Chan A, van Noesel M, Baas F, Caron H, Eggert A, Versteeg R. The Phox2B homeobox gene is mutated in sporadic neuroblastomas. *Oncogene* 2004;**23**:9280–8.
216. **Perri P**, Bachetti T, Longo L, Matera I, Seri M, Tonini GP, Ceccherini I. PHOX2B mutations and genetic predisposition to neuroblastoma. *Oncogene* 2005;**24**:3050–3.
217. **McConville C**, Reid S, Baskcomb L, Douglas J, Rahman N. PHOX2B analysis in non-syndromic neuroblastoma cases shows novel mutations and genotype-phenotype associations. *Am J Med Genet A* 2006;**140**:1297–301.
218. **Gozal D**. Congenital central hypoventilation syndrome: an update. *Pediatr Pulmonol* 1998;**26**:273–82.
219. **Roshkow JE**, Haller JO, Berdon WE, Sane SM. Hirschsprung's disease, Ondine's curse, and neuroblastoma—manifestations of neurocristopathy. *Pediatr Radiol* 1988;**19**:45–9.
220. **Levard G**, Boige N, Vitoux C, Aigrain Y, Boureau M, Navarro J. [Neurocristopathy. The association of Hirschsprung's disease-ganglioneuroma with autonomic nervous system dysfunction in 2 children]. *Arch Fr Pediatr* 1989;**46**:595–7.
221. **Weese-Mayer DE**, Silvestri JM, Marazita ML, Hoo JJ. Congenital central hypoventilation syndrome: inheritance and relation to sudden infant death syndrome. *Am J Med Genet* 1993;**47**:360–7.
222. **Croaker GD**, Shi E, Simpson E, Cartmill T, Cass DT. Congenital central hypoventilation syndrome and Hirschsprung's disease. *Arch Dis Child* 1998;**78**:316–22.
223. **Weese-Mayer DE**, Berry-Kravis EM, Zhou L, Maher BS, Silvestri JM, Curran ME, Marazita ML. Idiopathic congenital central hypoventilation syndrome: analysis of genes pertinent to early autonomic nervous system embryologic development and identification of mutations in PHOX2b. *Am J Med Genet* 2003;**123A**:267–78.
224. **Matera I**, Bachetti T, Puppo F, Di Duca M, Morandi F, Casiraghi GM, Cilio MR, Hennekam R, Hofstra R, Schober JG, Ravazzolo R, Ottonello G, Ceccherini I. PHOX2B mutations and polyalanine expansions correlate with the severity of the respiratory phenotype and associated symptoms in both congenital and late onset Central Hypoventilation syndrome. *J Med Genet* 2004;**41**:373–80.
225. **Weese-Mayer DE**, Berry-Kravis EM, Zhou L. Adult identified with congenital central hypoventilation syndrome—mutation in PHOX2b gene and late-onset CHS. *Am J Respir Crit Care Med* 2005;**171**:88.
226. **Waardenburg PJ**. A new syndrome combining developmental anomalies of the eyelids, eyebrows and nose root with pigmentary defects of the iris and head hair and with congenital deafness. *Am J Hum Genet* 1951;**3**:195–253.
227. **Hageman MJ**, Delleman JW. Heterogeneity in Waardenburg syndrome. *Am J Hum Genet* 1977;**29**:468–85.
228. **Jacobs JM**, Wilson J. An unusual demyelinating neuropathy in a patient with Waardenburg's syndrome. *Acta Neuropathol (Berl)* 1992;**83**:670–4.
229. **Weinberg AG**, Currarino G, Besserman AM. Hirschsprung's disease and congenital deafness. Familial association. *Hum Genet* 1977;**38**:157–61.
230. **Brunoni D**, Joffe R, Farah LM, Cunha AJ. Syndrome identification case report 92: Hirschsprung megacolon, cleft lip and palate, mental retardation, and minor congenital malformations. *J Clin Dysmorphol* 1983;**1**:20–2.
231. **Merkler RG**, Solish SB, Scherzer AL. Meningocele and Hirschsprung disease: theoretical and clinical significance. *Pediatrics* 1985;**76**:299–300.
232. **Papin C**, van Grunsven LA, Verschueren K, Huylebroeck D, Smith JC. Dynamic regulation of Brachyury expression in the amphibian embryo by XSIP1. *Mech Dev* 2002;**111**(1–2):37–46.
233. **Van de Putte T**, Francis A, Nelles L, van Grunsven LA, Huylebroeck D. Neural crest-specific removal of Zfh1b in mouse leads to a wide range of neurocristopathies reminiscent of Mowat-Wilson syndrome. *Hum Mol Genet* 2007;**16**:1423–36.
234. **Hurst JA**, Markiewicz M, Kumar D, Brett EM. Unknown syndrome: Hirschsprung's disease, microcephaly, and iris coloboma: a new syndrome of defective neuronal migration. *J Med Genet* 1988;**25**:494–7.
235. **Halal F**, Morel J. The syndrome of Hirschsprung disease, microcephaly, unusual face, and mental retardation. *Am J Med Genet* 1990;**37**:106–8.
236. **Reish O**, Gorlin RJ, Hordinsky M, Rest EB, Burke B, Berry SA. Brain anomalies, retardation of mentality and growth, ectodermal dysplasia, skeletal malformations, Hirschsprung disease, ear deformity and deafness, eye hypoplasia, cleft palate, cryptorchidism, and kidney dysplasia/hypoplasia (BRESEK/BRESHECK): new X-linked syndrome? *Am J Med Genet* 1997;**68**:386–90.

237. **Tobin JL**, Beales PL. Bardet-Biedl syndrome: beyond the cilium. *Pediatr Nephrol* 2007;**22**:926–36.
238. **Stone DL**, Slavotinek A, Bouffard GG, Banerjee-Basu S, Baxevanis AD, Barr M, Biesecker LG. Mutation of a gene encoding a putative chaperonin causes McKusick-Kaufman syndrome. *Nat Genet* 2000;**25**:79–82.
239. **Slavotinek AM**, Stone EM, Myktytn K, Heckenlively JR, Green JS, Heon E, Musarella MA, Parfrey PS, Sheffield VC, Biesecker LG. Mutations in MKKS cause Bardet-Biedl syndrome. *Nat Genet* 2000;**26**:15–16.
240. **Wassif CA**, Maslen C, Kachilele-Linjewile S, Lin D, Linck LM, Connor WE, Steiner RD, Porter FD. Mutations in the human sterol delta7-reductase gene at 11q12-13 cause Smith-Lemli-Opitz syndrome. *Am J Hum Genet* 1998;**63**:55–62.
241. **Waterham HR**, Wijburg FA, Hennekam RC, Vreken P, Poll-The BT, Dorland L, Duran M, Jira PE, Smeitink JA, Wevers RA, Wanders RJ. Smith-Lemli-Opitz syndrome is caused by mutations in the 7-dehydrocholesterol reductase gene. *Am J Hum Genet* 1998;**63**:329–38.
242. **Sulisalo T**, Sistonen P, Hastbacka J, Wadelius C, Makitie O, de la Chapelle A, Kaitila I. Cartilage-hair hypoplasia gene assigned to chromosome 9 by linkage analysis. *Nat Genet* 1993;**3**:338–41.
243. **de Pontual L**, Pelet A, Trochet D, Jaubert F, Espinosa-Parrilla Y, Munnich A, Brunet JF, Goridis C, Feingold J, Lyonnet S, Amiel J. Mutations of the RET gene in isolated and syndromic Hirschsprung's disease in human disclose major and modifier alleles at a single locus. *J Med Genet* 2006;**43**:419–23.
244. **Miao X**, Garcia-Barcelo MM, So MT, Leon TY, Lau DK, Liu TT, Chan EK, Lan LC, Wong KK, Lui VC, Tam PK. Role of RET and PHOX2B gene polymorphisms in risk of Hirschsprung's disease in Chinese population. *Gut* 2007;**56**:736.
245. **Hofstra RM**, Elfferich P, Osinga J, Verlind E, Fransen E, Lopez Pison J, de Die-Smulders CE, Stolte-Dijkstra I, Buys CH. Hirschsprung disease and L1CAM: is the disturbed sex ratio caused by L1CAM mutations? *J Med Genet* 2002;**39**:E11.
246. **Parisi MA**, Kapur RP, Neilson I, Hofstra RM, Holloway LW, Michaelis RC, Leppig KA. Hydrocephalus and intestinal aganglionosis: is L1CAM a modifier gene in Hirschsprung disease? *Am J Med Genet* 2002;**108**:51–6.
247. **Ikeda K**, Goto S. Additional anomalies in Hirschsprung's disease: an analysis based on the nationwide survey in Japan. *Z Kinderchir* 1986;**41**:279–81.
248. **Edward E**, Ecker J, Christakis N, Folkman J. Hirschsprung's disease: associated abnormalities and demography. *J Pediatr Surg* 1992;**27**:76.
249. **Russell MB**, Russell CA, Niebuhr E. An epidemiological study of Hirschsprung's disease and additional anomalies. *Acta Paediatr* 1994;**83**:68–71.
250. **Sarioglu A**, Tanyel FC, Buyukpamukcu N, Hicsonmez A. Hirschsprung-associated congenital anomalies. *Eur J Pediatr Surg* 1997;**7**:331–7.
251. **Lore F**, Di Cairano G, Talidis F. Unilateral renal agenesis in a family with medullary thyroid carcinoma. *N Engl J Med* 2000;**342**:1218–9.
252. **Whalen TV Jr**, Asch MJ. Report of two patients with hypertrophic pyloric stenosis and Hirschsprung's disease. Coincident or common etiology? *Am Surg* 1985;**51**:480–1.
253. **Sayed M**, al-Alaiyan S. Agenesis of corpus callosum, hypertrophic pyloric stenosis and Hirschsprung disease: coincidence or common etiology? *Neuropediatrics* 1996;**27**:204–6.
254. **Janik JP**, Wayne ER, Janik JS, Price MR. Ileal atresia with total colonic aganglionosis. *J Pediatr Surg* 1997;**32**:1502–3.
255. **McCallion AS**, Stames E, Conlon RA, Chakravarti A. Phenotype variation in two-locus mouse models of Hirschsprung disease: tissue-specific interaction between Ret and Ednrb. *Proc Natl Acad Sci U S A* 2003;**100**:1826–31.

Date for your diary

International Forum on Quality & Safety in Health Care

22–25 April 2008

Le Palais de Congrès de Paris

Paris, France

<http://www.internationalforum.bmj.com>

Why attend?

- ▶ Join over 1000 healthcare professionals from over 40 countries worldwide
- ▶ Learn from experienced leaders and improvement experts
- ▶ Find out what is current in quality and safety
- ▶ Gain new skills and tools for creating change in your organisation
- ▶ Take home practical solutions for improvement methods
- ▶ Network with like-minded colleagues

This is a premier event for those dedicated to improving quality and safety in healthcare. Our focus is on practical, take-home ideas that will leave you inspired to implement valuable, lasting change on your return to the workplace.

Register online from January 2008 onwards

For more information on the forum visit - <http://www.internationalforum.bmj.com>