



Editor's choice
Scan to access more
free content

Combination of palmoplantar keratoderma and hair shaft anomalies, the warning signal of severe arrhythmogenic cardiomyopathy: a systematic review on genetic desmosomal diseases

Laura Polivka, Christine Bodemer, Smail Hadj-Rabia

► Additional material is published online only. To view please visit the journal online (<http://dx.doi.org/10.1136/jmedgenet-2015-103403>).

Service de Dermatologie, Centre de référence MAGEC, INSERM1163, Institut Imagine Université Paris Descartes, Paris Sorbonne Cité, Faculté de Médecine et AP-HP Necker-Enfants Malades, Paris, France

Correspondence to

Pr Smail Hadj-Rabia, Service de Dermatologie Université Paris Descartes, Paris Sorbonne Cité, Faculté de Médecine et AP-HP Necker-Enfants Malades, 149 rue de Sèvres, 75743 Paris Cedex 15, France; smail.hadj@inserm.fr

Received 23 July 2015

Revised 18 August 2015

Accepted 21 August 2015

Published Online First

23 September 2015

ABSTRACT

Inherited desmosomal diseases are characterised by skin and/or cardiac features. Dermatological features might be a clue in the determination of the underlying life-threatening cardiac disease. This article aims to propose a dermatological algorithm for the diagnosis of desmosomal diseases after a systematic review of published articles. Palmoplantar keratoderma (PPK), hair shaft anomalies and skin fragility are the major features in the 458 patients analysed. Isolated PPK or isolated hair shaft anomalies are associated with a desmosomal disease limited to skin. The combination of PPK and hair shaft anomalies was recorded in 161 patients, and this association is at high risk of cardiac disease (129/161, 80.1%). Skin features had led to cardiac monitoring in only 2.3% of those patients. We delineated three major phenotypes: the PPK–hair shaft anomalies–non-fragile skin subtype (77%), always associated with cardiac involvement; the PPK–hair shaft anomalies–skin fragility–normal cardiac function subtype (19.9%), frequently associated with *PKP1* mutations; the PPK–hair shaft anomalies–skin fragility–cardiac involvement subtype (3.1%), always due to *DSP* mutations. Three mutation hotspots in *DSP* and *JUP* account for 90.8% of the patients with cardiac involvement. The combination of PPK and hair shaft anomalies justifies long-term cardiac monitoring.

INTRODUCTION

Desmosomes are intercellular junctions providing strong adhesion between cells by anchoring intermediate filaments to the plasma membrane. They are abundant in the heart and epidermis. Desmosomes play an important role in maintaining the integrity of these tissues and in signal transduction pathways.^{1 2} The desmosomal complex scaffolding includes armadillo proteins plakoglobin (PG) and plakophilins (PKP, isoforms 1 and 2), cadherins desmocollin (DSC, isoforms 1–3) and desmoglein (DSG, isoforms 1–4), and plakins desmoplakin (DSP).³ Corneodesmosin (CDSN), a component of corneodesmosome, is involved in the cohesion of corneocytes. All these proteins are present in the epidermis while five participate in the cardiomyocyte desmosomes: PKP2, DSP, PG, DSC2 and DSG2.

Since the first identification of *PKP1* mutation, several cases of desmosomal genodermatoses have been reported.⁴ Autosomal dominant or recessive mutations in one of the genes encoding for a

desmosomal protein may cause dermatological and/or cardiac abnormalities.^{5 6}

Disease severity is related to cardiac involvement corresponding to an arrhythmogenic cardiomyopathy. Arrhythmogenic cardiomyopathy is a progressive genetic cardiomyopathy characterised by myocyte degeneration followed by a fatty and fibrous replacement of the ventricular myocardium. Depending on the more involved ventricle, three arrhythmogenic cardiomyopathy subtypes are described: classic right dominant, left dominant and biventricular. The first clinical presentation of each of these subtypes is an episode of arrhythmia.⁷

Dermatological features are a clue for the clinical and molecular diagnosis of desmosomal diseases. They justify cardiac investigations and follow-up. Palmoplantar keratoderma (PPK) is easily recognisable while skin fragility, and hair and nail anomalies might be hardly perceptible.⁸

We conducted a systematic review of the published data in order to propose a clinical and molecular algorithm for the diagnosis of desmosomal diseases with dermatological features.

MATERIALS AND METHODS

A systematic MEDLINE search, using Medical Subject Heading terms, covered 1995 through March 2015. The following terms were used in association with ‘mutations’: ‘plakoglobin’; ‘Naxos disease’; ‘plakophilin’; ‘desmoplakin’; ‘desmoglein’; ‘desmocollin’; ‘corneodesmosin’. Full text articles were systematically read. References quoted in the articles were checked. Articles were retained based on the following criteria: (1) at least one identified mutation in the following genes: *JUP* (junctional plakoglobin), *PKP1*, *PKP2*, *DSP*, *DSG1* to *4*, *DSC1*–*3* and *CDSN*; (2) description of the cutaneous phenotype. Articles focusing on extracutaneous manifestations and/or cardiac involvement only were excluded. Redundant articles were excluded (figure 1). Data were extracted from each article and recorded in standardised form focusing on gender, age, dermatological, cardiac and other manifestations. Family history, mutation(s), mode of inheritance, ethnic background, epidemiological and clinical data were recorded. All the available pictures were carefully analysed in order to improve the description of dermatological manifestations. Sequence variations were checked and actualised using ENSEMBL software.



CrossMark

To cite: Polivka L, Bodemer C, Hadj-Rabia S. *J Med Genet* 2016;**53**:289–295.

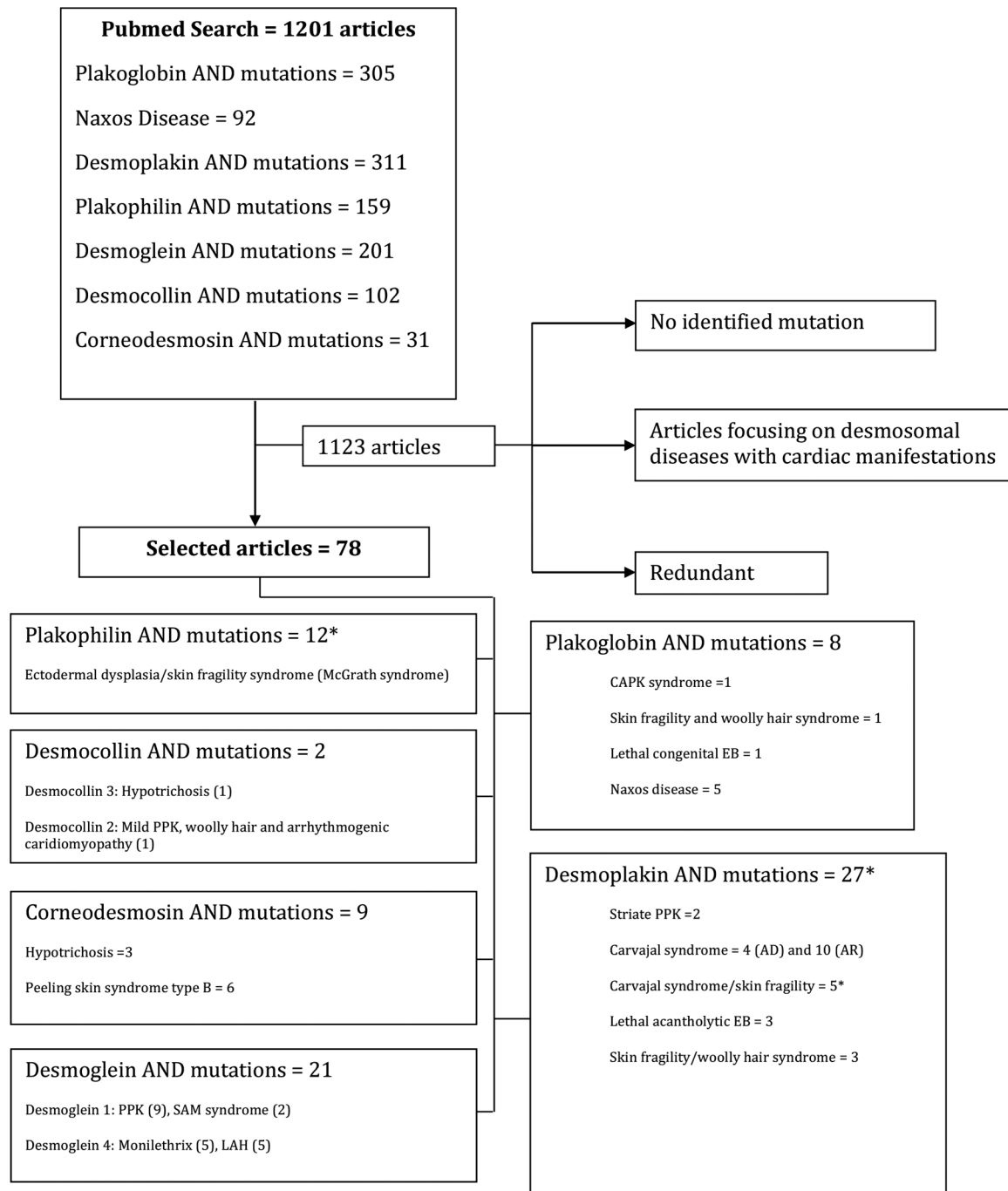


Figure 1 Desmosomal diseases: flow chart of the articles' selection process. *Reference 31 focuses on both *PKP1* and *DSP* genes mutations. AD, autosomal dominant; AR, autosomal recessive; CAPK, cardiomyopathy, alopecia and PPK; EB, epidermolysis bullosa; LAH, localised autosomal recessive hypotrichosis; PPK, palmoplantar keratoderma; SAM, skin dermatitis, multiple allergies, metabolic wasting.

RESULTS

A total of 78 articles were retained. They reported 458 patients carrying at least one mutation in one of the epidermal desmosomal genes. For one family, the total of affected members was not specified.⁹ Among the 458 patients, 161 had the combination of PPK and hair shaft anomalies (ie, woolly and/or sparse and/or short hair or congenital atrichia). Among those 161, 129 had cardiac involvement, including 63 patients (48.8%) who experienced clinical manifestations, that is, syncope, stroke, heart failure, arrhythmias or sudden death, before cardiac disease diagnosis. For three patients only (2.3%), the initial detection of dermatological features had led to cardiac

explorations. For the 63 remaining patients, the information was not available. Results were gathered according to the disease-causing gene (see online supplementary tables S1–S6).

JUP mutations

Within the 305 'plakoglobin mutations' and 92 'Naxos disease' references, eight were retained (see online supplementary table S1). They correspond to 82 patients, all carrying a recessive *JUP* mutation. Male-to-female ratio was 1.07 for the 68.3% of patients for whom the information was available. Among them, 74 patients carry the Naxos homozygous deletion (c.2157del2, exon 14).^{10–14} The Naxos phenotype is

characterised by diffuse PPK, woolly hair and classic right dominant arrhythmogenic cardiomyopathy in all reported patients. Two Turkish related patients carried a homozygous missense mutation (c.794G>A, exon 4).¹⁵ Their phenotype was close to Naxos syndrome and characterised by the association of cardiomyopathy (classic right dominant arrhythmogenic cardiomyopathy), alopecia (atrachia) and PPK (CAPK syndrome). In patients with Naxos and CAPK syndromes, symptomatic cardiac involvement started during the second decade (13–43 years).^{12–15}

Five patients, aged 6 months to 14 years, presented with the association of skin fragility, woolly hair, diffuse PPK and normal cardiac function. For them, the repeated cardiac monitoring (echocardiography and 12-lead ECG) was reported as normal at the time of publication. Two different homozygous mutations were found: c.71C>A (exon 2) and c.468G>A (exon 3).¹⁶ In patients with *JUP* mutation, the woolly hair appears from birth, whereas PPK develops later after the first year of life.

The last female patient presented with lethal congenital generalised epidermolysis bullosa and complete absence of scalp hair at birth. She died at 12 days of life, and carried a homozygous nonsense mutation (c.1615C>T; exon 9).¹⁷

DSP mutations

Among the 311 ‘desmoplakin mutations’ references, 27 were retained (see online supplementary table S2). A total of 93 patients carrying either an autosomal dominant or recessive mutation in *DSP* were found. Male-to-female ratio was 0.96 for the 96.8% of patients for whom the information was available.

Two autosomal dominant (39 cases) and four autosomal recessive (54 cases) cutaneous syndromes were described. Two large families with a striate PPK, characterised by linear and focal hyperkeratosis of the palms and soles, were reported. The three patients of the first family carried a heterozygous splice site mutation (c.939+1G>A, intron 7), while the 27 patients of the second family carried the heterozygous nonsense mutation (p.Q331X, exon 8).^{18 19}

The first autosomal recessive syndrome related to *DSP* mutations is known as Carvajal syndrome. Thirty-seven patients carrying either a homozygous or a compound heterozygous mutation in *DSP* were identified. All the mutations were located in exon 23 or 24, except for one compound heterozygous patient who carried mutations in exons 9 and 16.^{20–29} The Carvajal phenotype is similar to Naxos disease: striate or focal PPK, woolly ± sparse hair and arrhythmogenic cardiomyopathy involving more frequently the left ventricle (left dominant arrhythmogenic cardiomyopathy).⁷ The median age of the first cardiac manifestation was 8 years (3–35). One 6-year-old boy had normal cardiac ultrasound at the time of publication.²⁹

Nine patients presented with PPK, woolly and/or sparse hair, left dominant arrhythmogenic cardiomyopathy associated with oligodontia for eight and leukonychia or nail dystrophy in four of them. All of them carried a heterozygous *DSP* mutation in exon 13 (one mutation) or 14 (three mutations). The median age of the first cardiac symptom was 12 years (7–14).^{30–33}

Three additional autosomal recessive syndromes, related to *DSP* mutations sharing the skin fragility feature, were reported in a total of 17 patients: (1) five patients carrying heterozygous compound mutations, with at least one of the mutation located in exon 23 or 24, presented with the combination of Carvajal syndrome, skin fragility ± ectodermal dysplasia features. Four of the five patients presented with nail dystrophy. The first cardiac symptom occurred early at the median age of 35 months (1–14 years). Blisters or erosions occurred spontaneously or after very mild trauma.^{34–38} (2) Eight patients presented with

skin fragility associated with woolly hair. All the patients had nail dystrophy. Cardiac function was normal. At the time of publication, one 4½-year-old boy had normal cardiac monitoring, including ECG and echocardiography.³⁹ One 14-year-old female patient with her four relatives, aged 3–16 years, had normal clinical cardiac examination at the time of publication, but three of them refused cardiac monitoring.⁴⁰ For the two other patients, age and type of cardiac exploration were not specified.⁴¹ In patients with *DSP* mutation, the woolly hair appears from birth, whereas PPK develops after the first year of life. (3) The four last compound heterozygous patients died during their first month of life. They presented with lethal acantholytic epidermolysis bullosa, associated with alopecia and onychia. Ultrasound showed cardiac hypocontractility in one patient only. For these three autosomal recessive syndromes, skin fragility was noticed at birth, or soon after, except for one patient for whom skin fragility started at 2 years.^{42–44}

PKP1 mutations

Among the 159 ‘plakophilin mutations’ references, 12 were retained (see online supplementary table S3). Nineteen patients carrying a homozygous or a heterozygous compound mutation were published. Male-to-female ratio was 1.83 for the 88.9% of patients for whom the information was available.

The corresponding McGrath syndrome, or ectodermal dysplasia/skin fragility syndrome, is characterised by the association of skin fragility, sparse and short hair, PPK and nail dystrophy. Cheilitis and/or perioral fissuring or redness, reported in at least 11 patients, are considered as a discriminative clinical feature. Cardiac function is normal. Five patients (26.3%) presented with reduced sweating and six with normal sweating. Information was not available for the last eight patients. Skin fragility started at birth or soon after, except for one patient for whom it started at 18 years.^{4 35 45–54}

DSG1 and DSG4 mutations

Among the 201 ‘desmoglein mutations’ references, 21 were retained. Eleven articles correspond to *DSG1* and 10 to *DSG4* mutation (see online supplementary table S4).

Ninety-three patients had a heterozygous or homozygous mutation in *DSG1*. Male-to-female ratio was 0.96 for 94.6% of the patients for whom the information was available. *DSG1* mutations are associated with autosomal dominant striate PPK and with autosomal recessive skin dermatitis, multiple allergies and metabolic wasting syndrome, or SAM syndrome. Eighty-six patients presented with isolated PPK; among them, 69 had striate PPK, and four had diffuse PPK. Information was not available for the 13 remaining patients. Seventeen different heterozygous mutations were reported.^{55–63} Seven patients belonging to three unrelated families carry three different homozygous *DSG1* mutations. They presented with the association of congenital erythroderma, hypotrichosis or curly hair, striate PPK (for at least three of them), severe food allergy, high level of IgE and recurrent infections with severe metabolic wasting (for six of them). One patient presented with ventricular septal defect. The six remaining patients had no cardiac manifestation.^{64 65}

Sixty-six patients had a recessive mutation in *DSG4*. Male-to-female ratio was 1.03 for 98.5% of the patients for whom the information was available. Two phenotypes are associated with recessive *DSG4* mutations: localised autosomal recessive hypotrichosis (LAH)^{66–70} and monilethrix.^{71–75} In LAH, hypotrichosis affects the hair of the scalp, trunk and extremities, and spares facial, pubic and axillary regions. An in-frame intragenic homozygous deletion (Ex5_8del) was reported in 34 of the 41 patients

with LAH. Two other homozygous mutations were identified (c. GG384–385TT and c.87delG). Monilethrix, reported in 25 patients, is characterised by periodic beaded hair shafts and pronounced hair fragility leading to hair loss. In these two diseases, manifestations started at birth or during the first month of life.

DSC2 and DSC3 mutations

Among the 102 ‘desmocollin mutations’, two articles, corresponding to six patients, were retained (see online supplementary table S5). While recessive mutations in *DSC2* are known to cause isolated arrhythmogenic cardiomyopathy, two related patients presented with the combination of left cardiac involvement, woolly hair and mild PPK. Both carry a *DSC2* homozygous mutation (c.1841delG, exon 12).⁷⁶ Hypotrichosis, the only phenotype related to *DSC3* mutations, is reported in four patients of the same Afghan family. They carry a homozygous mutation (c.2129T>G, exon 14). They presented with sparse and fragile whole body hair.⁷⁷

CDSN mutations

Within the 31 ‘corneodesmosin mutations’ references, nine were retained (see online supplementary table S6). Mutations in *CDSN* are associated with hypotrichosis simplex of the scalp

(HSS) and peeling skin syndrome type B (PSS). At least, 99 patients carried a mutation in *CDSN*. The total of affected relatives was not specified for one Danish family with HSS.⁹ Male-to-female ratio was 1.28 for 97% of the patients for which the information was available.

HSS is characterised by diffuse progressive scalp hair loss from childhood to adulthood. So far, more than 88 patients belonging to five HSS families have been reported. Four different heterozygous mutations in the exon 2 were identified.^{9 78 79} PSS is characterised by an inflammatory lifelong peeling of the stratum corneum on the whole body. Eleven patients with PSS were reported. The inflammatory exfoliation started at birth or during the first week of life (nine patients) or at 3 years (one patient). Information was not available for the last patient. To date, food allergies and a high level of IgE are reported. Six different homozygous mutations in exon 2 of *CDSN* were identified.^{80–85}

DISCUSSION

Skin fragility, hair shaft anomalies and PPK are the main dermatological features of cutaneous desmosomal diseases. We propose a flow chart to detect the patient at risk of sudden death due to cardiac involvement and a strategy of gene sequencing (figure 2).

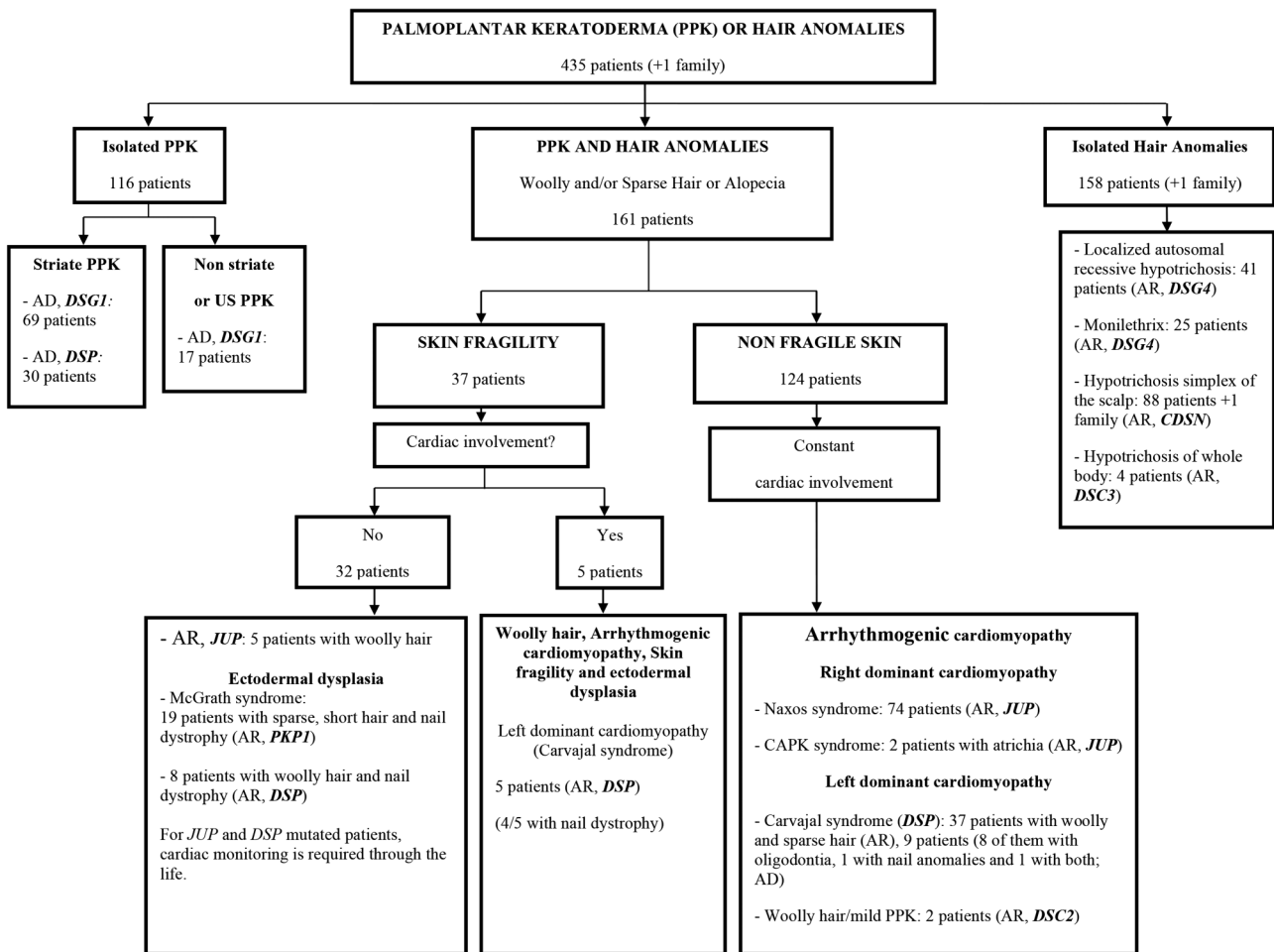


Figure 2 Desmosomal diseases with cutaneous features: clinical and molecular diagnosis flow chart. Desmosomal diseases were classified according to the three commonly associated dermatological manifestations: palmo-plantar keratoderma (PPK), hair shaft anomalies and skin fragility, when reported PPK occurred after 1 year of age. PSS (11 patients, AR, *CDSN*) and SAM syndrome (7 patients, AR, *DSG1*) were not included because their main symptoms are inflammatory skin exfoliation and erythroderma, respectively. Neither was lethal acantholytic epidermolysis bullosa (1 patient, AR, *JUP*; 4 patients, AR, *DSP*) as patients died during their first month of life. Therefore, their main manifestations were congenital epidermolysis bullosa and ectodermal dysplasia features (hair, nail and dental anomalies). AD, autosomal dominant; AR, autosomal recessive; CAPK, cardiomyopathy, alopecia and PPK; *CDSN*, corneodesmosin; *DSC*, desmocollin; *DSG*, desmoglein; *DSP*, desmoplakin; *JUP*, junctional plakoglobin; PKP1, plakophilin 1; PSS, peeling skin syndrome; SAM, skin dermatitis, multiple allergies, metabolic wasting; US, unspecified.

While isolated PPK or isolated hair shaft anomalies are associated with a desmosomal disease limited to skin, their combination is associated with classic right dominant (*JUP* mutations) or left dominant (*DSP* and *DSC2* mutations) arrhythmogenic cardiomyopathy in 80.1% (129) of the 161 reported patients with such association (PPK–hair shaft anomalies). In all the 129 reported patients, dermatological features occurred before cardiac manifestations, that is, hair shaft anomalies since birth and PPK after 1 year. For the earliest case, cardiac involvement is reported during the first year of life. Interestingly, the detection of skin features led to cardiac disease diagnosis by systematic monitoring in only 2.3% of the patients with PPK–hair shaft anomalies.^{33–37} Therefore, regular cardiac monitoring is mandatory in all patients presenting with PPK–hair shaft anomalies, even in the absence of clinical cardiac manifestations. Importantly, 11.8% (19) of the remaining patients with PPK–hair shaft anomalies carried mutations in *PKP1*, which is not expressed in the cardiac desmosome. Finally, only 8.1% (13) patients with PPK–hair shaft anomalies, due to a recessive mutation in *JUP* (5) or *DSP* (8), were reported with normal cardiac function. Considering their median age at the time of publication (4 years (6 months to 17 years)), late cardiac involvement is not excluded.^{16–39–41}

The clinical diagnosis of the third dermatological feature, known as ‘skin fragility’, might be challenging. The skin fragility spectrum ranges from easy recognisable blisters to superficial linear erosions accompanying scratching. Taking skin fragility into account, three major clinical subtypes might be individualised:

- ▶ The PPK–hair shaft anomalies–non-fragile skin subtype, reported in 77% (124/161) of the patients, was always associated with arrhythmogenic cardiomyopathy. Recessive mutations of *JUP*, *DSP* and *DSC2* were found in all but nine patients (7.3%) who carried a heterozygous mutation of *DSP*.
- ▶ The PPK–hair shaft anomalies–skin fragility–cardiac involvement subtype is reported in 3.1% (5/161) of the patients or 13.5% (5/37) of the patients with skin fragility. For them, homozygous or compound heterozygous mutations of *DSP* were always identified.
- ▶ The PPK–hair shaft anomalies–skin fragility–normal cardiac function subtype, reported in 19.9% (32/161) of the patients, might be divided into patients carrying recessive *PKP1* mutations and patients carrying recessive *JUP* or *DSP* mutations. For the former, considering *PKP1* tissue expression, cardiac follow-up is not required. For the latter, additional data are mandatory in order to exclude late cardiac involvement during adulthood.

Two additional severe diseases are associated with desmosomal gene mutations. Lethal epidermolysis bullosa, reported in five patients, associates epidermal detachment to ectodermal dysplasia features. The major concerns are early medical care requiring neonatal intensive care unit and positive diagnosis. Erythroderma seems to be constant in the seven patients with SAM syndrome.

Dominant or recessive mutations of *JUP* or *DSP* were identified in 87% (140) of the 161 patients with PPK–hair shaft anomalies. The ratio reached 98.4% (127/129) in case of cardiac involvement. In this group, the Naxos deletion (c.2157del2, exon 14) accounts for 97.4% (74/76) of the patients with *JUP*. Mutations in the long exons 23 and/or 24 accounted for 83.5% of the patients with *DSP* with PPK–hair shaft anomalies. These three mutation hotspots, accounting for 90.8%, of PPK–hair shaft anomalies with cardiac involvement cases might be sequenced first in this situation. Cardiac involvement occurring during the first 5 years of life suggested recessive *DSP* mutations. In case of normal cardiac function,

identification of a recessive *PKP1* mutation leads to stoppage of cardiac monitoring. Identification of a recessive mutation of *JUP* or *DSP* justifies cardiac monitoring throughout life.

Oligodontia and onychodystrophy were reported in at least 24.8% (40/161) of patients with PPK–hair shaft anomalies. With hair shaft anomalies, they represented the major features of ectodermal dysplasias. Unfortunately, nail, tooth and sweating anomalies were not detailed. Additional data might help to refine the phenotype-to-genotype correlation and to classify desmosomal skin disorders in the group of ectodermal dysplasias.

Finally, considering this extensive review of publications on desmosomal diseases, the combination of PPK and hair shaft anomalies justify long-term cardiac monitoring. This monitoring might be stopped in the situation of the identification of *PKP1* gene mutation only.

Contributors SH-R designed the work. LP collected the data. SH-R and LP analysed the data and wrote the manuscript. CB participated in the critical revision of the manuscript for important intellectual content. All the authors agreed with the integrity of any part of the work.

Competing interests None declared.

Provenance and peer review Commissioned; externally peer reviewed.

Data sharing statement All the data we collected were reported in the original article or in the online supplementary data section. We are available to answer any question.

REFERENCES

- 1 Chidgey M, Brakebusch C, Gustafsson E, Cruchley A, Hail C, Kirk S, Merritt A, North A, Tselepis C, Hewitt J, Byrne C, Fassler R, Garrod D. Mice lacking desmocollin 1 show epidermal fragility accompanied by barrier defects and abnormal differentiation. *J Cell Biol* 2001;155:821–32.
- 2 Brennan D, Hu Y, Joubert S, Choi YW, Whitaker-Menezes D, O'Brien T, Uitto J, Rodeck U, Mahoney MG. Suprabasal Dsg2 expression in transgenic mouse skin confers a hyperproliferative and apoptosis-resistant phenotype to keratinocytes. *J Cell Sci* 2007;120:758–71.
- 3 Nekrasova O, Green KJ. Desmosome assembly and dynamics. *Trends Cell Biol* 2013;23:537–46.
- 4 McGrath JA, McMillan JR, Shemanko CS, Runswick SK, Leigh IM, Lane EB, Garrod DR, Eady RA. Mutations in the plakophilin 1 gene result in ectodermal dysplasia/skin fragility syndrome. *Nat Genet* 1997;17:240–4.
- 5 Protonotarios N, Tsatsopoulou A, Scampardonis G. Arrhythmogenic cardiomyopathy with ectodermal dysplasia. *Am Heart J* 1988;116:1651–2.
- 6 Protonotarios N, Tsatsopoulou A, Patsourakos P, Alexopoulos D, Gezerlis P, Simitsis S, Scampardonis G. Cardiac abnormalities in familial palmoplantar keratosis. *Br Heart J* 1986;56:321–6.
- 7 Sen-Chowdhry S, McKenna WJ. When rare illuminates common: how cardiocutaneous syndromes transformed our perspective on arrhythmogenic cardiomyopathy. *Cell Commun Adhes* 2014;21:3–11.
- 8 Kelsell DP, Stevens HP. The palmoplantar keratodermas: much more than palms and soles. *Mol Med Today* 1999;5:107–13.
- 9 Levy-Nissenbaum E, Betz RC, Frydman M, Simon M, Lahat H, Bakhan T, Goldman B, Bygum A, Pierick M, Hillmer AM, Jonca N, Toribio J, Kruse R, Dewald G, Cichon S, Kubisch C, Guerrin M, Serre G, Nöthen MM, Pras E. Hypotrichosis simplex of the scalp is associated with nonsense mutations in *CDSN* encoding corneodesmosin. *Nat Genet* 2003;34:151–3.
- 10 McKoy G, Protonotarios N, Crosby A, Tsatsopoulou A, Anastasakis A, Coonar A, Norman M, Baboonian C, Jeffery S, McKenna WJ. Identification of a deletion in plakoglobin in arrhythmogenic right ventricular cardiomyopathy with palmoplantar keratoderma and woolly hair (Naxos disease). *Lancet* 2000;355:2119–24.
- 11 Protonotarios N, Tsatsopoulou A, Anastasakis A, Sevdalis E, McKoy G, Stratos K, Gatzoulis K, Tentolouris K, Spiliopoulou C, Panagiotakos D, McKenna W, Toutouzas P. Genotype-phenotype assessment in autosomal recessive arrhythmogenic right ventricular cardiomyopathy (Naxos disease) caused by a deletion in plakoglobin. *J Am Coll Cardiol* 2001;38:1477–84.
- 12 Narin N, Akcakus M, Gunes T, Celiker A, Baykan A, Uzum K, Ferahbas A. Arrhythmogenic right ventricular cardiomyopathy (Naxos disease): report of a Turkish boy. *Pacing Clin Electrophysiol PACE* 2003;26:2326–9.
- 13 Antoniadis L, Tsatsopoulou A, Anastasakis A, Syrris P, Asimaki A, Panagiotakos D, Zambartas C, Stefanadis C, McKenna WJ, Protonotarios N. Arrhythmogenic right ventricular cardiomyopathy caused by deletions in plakophilin-2 and plakoglobin (Naxos disease) in families from Greece and Cyprus: genotype-phenotype relations, diagnostic features and prognosis. *Eur Heart J* 2006;27:2208–16.

- 14 Lazaros G, Anastasakis A, Tsiachris D, Dilaveris P, Protonotarios N, Stefanadis C. Naxos disease presenting with ventricular tachycardia and troponin elevation. *Heart Vessels* 2009;24:63–5.
- 15 Erken H, Yari Z, Duman D, Kaya CT, Sayin T, Heper AO, Tekin M. Cardiomyopathy with alopecia and palmoplantar keratoderma (CAPK) is caused by a JUP mutation. *Br J Dermatol* 2011;165:917–21.
- 16 Cabral RM, Liu L, Hogan C, Dopping-Hepenstal PJ, Winik BC, Asial RA, Dobson R, Mein CA, Baselaga PA, Mellerio JE, Nanda A, Boente M del C, Kelsell DP, McGrath JA, South AP. Homozygous mutations in the 5' region of the JUP gene result in cutaneous disease but normal heart development in children. *J Invest Dermatol* 2010;130:1543–50.
- 17 Pigors M, Kiritsi D, Krümpelmann S, Wagner N, He Y, Podda M, Kohlhasse J, Hausser I, Bruckner-Tuderman L, Has C. Lack of plakoglobin leads to lethal congenital epidermolysis bullosa: a novel clinico-genetic entity. *Hum Mol Genet* 2011;20:1811–19.
- 18 Armstrong DK, McKenna KE, Purkis PE, Green KJ, Eady RA, Leigh IM, Hughes AE. Haploinsufficiency of desmoplakin causes a striate subtype of palmoplantar keratoderma. *Hum Mol Genet* 1999;8:143–8.
- 19 Whittock NV, Ashton GH, Dopping-Hepenstal PJ, Gratian MJ, Keane FM, Eady RA, McGrath JA. Striate palmoplantar keratoderma resulting from desmoplakin haploinsufficiency. *J Invest Dermatol* 1999;113:940–6.
- 20 Norgett EE, Hatsell SJ, Carvajal-Huerta L, Cabezas JC, Common J, Purkis PE, Whittock NV, Leigh IM, Stevens HP, Kelsell DP. Recessive mutation in desmoplakin disrupts desmoplakin-intermediate filament interactions and causes dilated cardiomyopathy, woolly hair and keratoderma. *Hum Mol Genet* 2000;9:2761–6.
- 21 Alcalai R, Metzger S, Rosenheck S, Meiner V, Chajek-Shaul T. A recessive mutation in desmoplakin causes arrhythmogenic right ventricular dysplasia, skin disorder, and woolly hair. *J Am Coll Cardiol* 2003;42:319–27.
- 22 Uzumcu A, Norgett EE, Dindar A, Uyguner O, Nisli K, Kayserili H, Sahin SE, Dupont E, Severs NJ, Leigh IM, Yuksel-Apak M, Kelsell DP, Wollnik B. Loss of desmoplakin isoform I causes early onset cardiomyopathy and heart failure in a Naxos-like syndrome. *J Med Genet* 2006;43:e5.
- 23 Christensen AH, Benn M, Bundgaard H, Tybaerg-Hansen A, Haunso S, Svendsen JH. Wide spectrum of desmosomal mutations in Danish patients with arrhythmogenic right ventricular cardiomyopathy. *J Med Genet* 2010;47:736–44.
- 24 Krishnamurthy S, Adhisivam B, Hamilton RM, Baskin B, Biswal N, Kumar M. Arrhythmogenic dilated cardiomyopathy due to a novel mutation in the desmoplakin gene. *Indian J Pediatr* 2011;78:866–9.
- 25 Williams T, Machann W, Kühler L, Hamm H, Müller-Höcker J, Zimmer M, Ertl G, Ritter O, Beer M, Schönberger J. Novel desmoplakin mutation: juvenile biventricular cardiomyopathy with left ventricular non-compaction and acantholytic palmoplantar keratoderma. *Clin Res Cardiol Off J Ger Card Soc* 2011;100:1087–93.
- 26 Rasmussen TB, Hansen J, Nissen PH, Palmfeldt J, Dalager S, Jensen UB, Kim WY, Heickendorff L, Mølgaard H, Jensen HK, Sørensen KE, Baandrup UT, Bross P, Mogensen J. Protein expression studies of desmoplakin mutations in cardiomyopathy patients reveal different molecular disease mechanisms. *Clin Genet* 2013;84:20–30.
- 27 Yesudian PD, Cabral RM, Ladusans E, Spinty S, Gibbs J, Fryer A, Christiano AM, Mendelsohn SS. Novel compound heterozygous mutations in the desmoplakin gene cause hair shaft abnormalities and culminate in lethal cardiomyopathy. *Clin Exp Dermatol* 2014;39:506–8.
- 28 Molho-Pessach V, Sheffer S, Siam R, Tams S, Siam I, Awwad R, Babay S, Golender J, Simanovsky N, Ramot Y, Zlotogorski A. Two novel homozygous desmoplakin mutations in Carvajal syndrome. *Pediatr Dermatol* 2015;32:641–6.
- 29 Pigors M, Schwiager-Briel A, Cosgarea R, Diaconeasa A, Bruckner-Tuderman L, Fleck T, Has C. Desmoplakin mutations with palmoplantar keratoderma, woolly hair and cardiomyopathy. *Acta Derm Venereol* 2015;95:337–40.
- 30 Norgett EE, Lucke TW, Bowers B, Munro CS, Leigh IM, Kelsell DP. Early death from cardiomyopathy in a family with autosomal dominant striate palmoplantar keratoderma and woolly hair associated with a novel insertion mutation in desmoplakin. *J Invest Dermatol* 2006;126:1651–4.
- 31 Chalabreysse L, Senni F, Bruyère P, Aime B, Ollagnier C, Bozio A, Bouvagnet P. A new hypo/oligodontia syndrome: Carvajal/Naxos syndrome secondary to desmoplakin-dominant mutations. *J Dent Res* 2011;90:58–64.
- 32 Boulé S, Fressart V, Laux D, Mallet A, Simon F, de Groote P, Bonnet D, Klug D, Charron P. Expanding the phenotype associated with a desmoplakin dominant mutation: Carvajal/Naxos syndrome associated with leukonychia and oligodontia. *Int J Cardiol* 2012;161:50–2.
- 33 Keller DI, Stepowski D, Balmer C, Simon F, Guenthard J, Bauer F, Itin P, David N, Drouin-Garraud V, Fressart V. De novo heterozygous desmoplakin mutations leading to Naxos-Carvajal disease. *Swiss Med Wkly* 2012;142:w13670.
- 34 Asimaki A, Syrris P, Ward D, Guetera LG, Saffitz JE, McKenna WJ. Unique epidermolytic bullous dermatosis with associated lethal cardiomyopathy related to novel desmoplakin mutations. *J Cutan Pathol* 2009;36:553–9.
- 35 Tanaka A, Lai-Cheong JE, Café MEM, Gontijo B, Salomão PR, Pereira L, McGrath JA. Novel truncating mutations in PKP1 and DSP cause similar skin phenotypes in two Brazilian families. *Br J Dermatol* 2009;160:692–7.
- 36 Mahoney MG, Sadowski S, Brennan D, Pikander P, Saukko P, Wahl J, Aho H, Heikinheimo K, Bruckner-Tuderman L, Fertala A, Peltonen J, Uitto J, Peltonen S. Compound heterozygous desmoplakin mutations result in a phenotype with a combination of myocardial, skin, hair, and enamel abnormalities. *J Invest Dermatol* 2010;130:968–78.
- 37 Vahlquist A, Virtanen M, Hellström-Pigg M, Dragomir A, Ryberg K, Wilson NJ, Östman-Smith I, Lu L, McGrath JA, Smith FJD. A Scandinavian case of skin fragility, alopecia and cardiomyopathy caused by DSP mutations. *Clin Exp Dermatol* 2014;39:30–4.
- 38 Antonov NK, Kingsbery MY, Rohena LO, Lee TM, Christiano A, Garzon MC, Lauren CT. Early-onset heart failure, alopecia, and cutaneous abnormalities associated with a novel compound heterozygous mutation in desmoplakin. *Pediatr Dermatol* 2015;32:102–8.
- 39 Smith FJD, Wilson NJ, Moss C, Dopping-Hepenstal P, McGrath JA. Compound heterozygous mutations in desmoplakin cause skin fragility and woolly hair. *Br J Dermatol* 2012;166:894–6.
- 40 Al-Owaini M, Wakil S, Shareef F, Al-Fatani A, Hamadah E, Haider M, Al-Hindi H, Awaji A, Khalifa O, Baz B, Ramadhan R, Meyer B. Novel homozygous mutation in DSP causing skin fragility-woolly hair syndrome: report of a large family and review of the desmoplakin-related phenotypes. *Clin Genet* 2011;80:50–8.
- 41 Whittock NV, Wan H, Morley SM, Garzon MC, Kristal L, Hyde P, McLean WHI, Pulkkinen L, Uitto J, Christiano AM, Eady RAJ, McGrath JA. Compound heterozygosity for non-sense and mis-sense mutations in desmoplakin underlies skin fragility/woolly hair syndrome. *J Invest Dermatol* 2002;118:232–8.
- 42 Jonkman MF, Pasmooij AMG, Pasmans SGMA, van den Berg MP, Ter Horst HJ, Timmer A, Pas HH. Loss of desmoplakin tail causes lethal acantholytic epidermolysis bullosa. *Am J Hum Genet* 2005;77:653–60.
- 43 Bolling MC, Veenstra MJ, Jonkman MF, Diercks GFH, Curry CJ, Fisher J, Pas HH, Bruckner AL. Lethal acantholytic epidermolysis bullosa due to a novel homozygous deletion in DSP: expanding the phenotype and implications for desmoplakin function in skin and heart. *Br J Dermatol* 2010;162:1388–94.
- 44 Hobbs RP, Han SY, van der Zwaag PA, Bolling MC, Jongbloed JDH, Jonkman MF, Getsios S, Paller AS, Green KJ. Insights from a desmoplakin mutation identified in lethal acantholytic epidermolysis bullosa. *J Invest Dermatol* 2010;130:2680–3.
- 45 McGrath JA, Hoeger PH, Christiano AM, McMillan JR, Mellerio JE, Ashton GH, Dopping-Hepenstal PJ, Lake BD, Leigh IM, Harper JL, Eady RA. Skin fragility and hypohidrotic ectodermal dysplasia resulting from ablation of plakophilin 1. *Br J Dermatol* 1999;140:297–307.
- 46 Whittock NV, Haftek M, Angoultant N, Wolf F, Perrot H, Eady RA, McGrath JA. Genomic amplification of the human plakophilin 1 gene and detection of a new mutation in ectodermal dysplasia/skin fragility syndrome. *J Invest Dermatol* 2000;115:368–74.
- 47 Hamada T, South AP, Mitsuhashi Y, Kinebuchi T, Bleck O, Ashton GHS, Hozumi Y, Suzuki T, Hashimoto T, Eady RA, McGrath JA. Genotype-phenotype correlation in skin fragility-ectodermal dysplasia syndrome resulting from mutations in plakophilin 1. *Exp Dermatol* 2002;11:107–14.
- 48 Sprecher E, Molho-Pessach V, Ingber A, Sagi E, Indelman M, Bergman R. Homozygous splice site mutations in PKP1 result in loss of epidermal plakophilin 1 expression and underlie ectodermal dysplasia/skin fragility syndrome in two consanguineous families. *J Invest Dermatol* 2004;122:647–51.
- 49 Steijlen PM, van Steensel MAM, Jansen BJH, Blokx W, van de Kerckhof PCM, Happle R, van Geel M. Cryptic splicing at a non-consensus splice-donor in a patient with a novel mutation in the plakophilin-1 gene. *J Invest Dermatol* 2004;122:1321–4.
- 50 Zheng R, Bu D-F, Zhu X-J. Compound heterozygosity for new splice site mutations in the plakophilin 1 gene (PKP1) in a Chinese case of ectodermal dysplasia-skin fragility syndrome. *Acta Derm Venereol* 2005;85:394–9.
- 51 Ersoy-Evans S, Erkin G, Fassih H, Chan I, Paller AS, Sürücü S, McGrath JA. Ectodermal dysplasia-skin fragility syndrome resulting from a new homozygous mutation, 888delC, in the desmosomal protein plakophilin 1. *J Am Acad Dermatol* 2006;55:157–61.
- 52 Boyce AE, McGrath JA, Techanukul T, Murrell DF, Chow CW, McGregor L, Warren LJ. Ectodermal dysplasia-skin fragility syndrome due to a new homozygous internal deletion mutation in the PKP1 gene. *Australas J Dermatol* 2012;53:61–5.
- 53 Hernández-Martín A, Torrelo A, Ciria S, Colmenero I, Aguilar A, Grimalt R, González-Sarmiento R. Ectodermal dysplasia-skin fragility syndrome: a novel mutation in the PKP1 gene. *Clin Exp Dermatol* 2013;38:787–90.
- 54 Abdalla EM, Has C. A plakophilin-1 gene mutation in an Egyptian family with ectodermal dysplasia-skin fragility syndrome. *Mol Syndromol* 2014;5:304–6.
- 55 Rickman D, Simrak D, Stevens HP, Hunt DM, King IA, Bryant SP, Eady RA, Leigh IM, Arneemann J, Magee AI, Kelsell DP, Buxton RS. N-terminal deletion in a desmosomal cadherin causes the autosomal dominant skin disease striate palmoplantar keratoderma. *Hum Mol Genet* 1999;8:971–6.
- 56 Hunt DM, Rickman L, Whittock NV, Eady RA, Simrak D, Dopping-Hepenstal PJ, Stevens HP, Armstrong DK, Hennies HC, Küster W, Hughes AE, Arneemann J, Leigh IM, McGrath JA, Kelsell DP, Buxton RS. Spectrum of dominant mutations in the desmosomal cadherin desmoglein 1, causing the skin disease striate palmoplantar keratoderma. *Eur J Hum Genet* 2001;9:197–203.

- 57 Kljuc A, Gilead L, Martinez-Mir A, Frank J, Christiano AM, Zlotogorski A. A nonsense mutation in the desmoglein 1 gene underlies striate keratoderma. *Exp Dermatol* 2003;12:523–7.
- 58 Keren H, Bergman R, Mizrahi M, Kashi Y, Sprecher E. Diffuse nonepidermolytic palmoplantar keratoderma caused by a recurrent nonsense mutation in DSG1. *Arch Dermatol* 2005;141:625–8.
- 59 Milingou M, Wood P, Masouyé I, McLean WH, Borradori L. Focal palmoplantar keratoderma caused by an autosomal dominant inherited mutation in the desmoglein 1 gene. *Dermatol Basel Switz* 2006;212:117–22.
- 60 Barber AG, Wajid M, Columbo M, Lubetkin J, Christiano AM. Striate palmoplantar keratoderma resulting from a frameshift mutation in the desmoglein 1 gene. *J Dermatol Sci* 2007;45:161–6.
- 61 Dua-Awereh MB, Shimomura Y, Kraemer L, Wajid M, Christiano AM. Mutations in the desmoglein 1 gene in five Pakistani families with striate palmoplantar keratoderma. *J Dermatol Sci* 2009;53:192–7.
- 62 Hershkovitz D, Lugassy J, Indelman M, Bergman R, Sprecher E. Novel mutations in DSG1 causing striate palmoplantar keratoderma. *Clin Exp Dermatol* 2009;34:224–8.
- 63 Zamiri M, Smith FJD, Campbell LE, Tetley L, Eady RA, Hodgins MB, McLean WHI, Munro CS. Mutation in DSG1 causing autosomal dominant striate palmoplantar keratoderma. *Br J Dermatol* 2009;161:692–4.
- 64 Samuelov L, Sarig O, Harmon RM, Rapaport D, Ishida-Yamamoto A, Isakov O, Koetsier JL, Gat A, Goldberg I, Bergman R, Spiegel R, Eytan O, Geller S, Peleg S, Shomron N, Goh CSM, Wilson NJ, Smith FJD, Pohler E, Simpson MA, McLean WHI, Irvine AD, Horowitz M, McGrath JA, Green KJ, Sprecher E. Desmoglein 1 deficiency results in severe dermatitis, multiple allergies and metabolic wasting. *Nat Genet* 2013;45:1244–8.
- 65 Has C, Jakob T, He Y, Kiritsi D, Hausser I, Bruckner-Tuderman L. Loss of desmoglein 1 associated with palmoplantar keratoderma, dermatitis and multiple allergies. *Br J Dermatol* 2015;172:257–61.
- 66 Kljuc A, Bazzi H, Sundberg JP, Martinez-Mir A, O'Shaughnessy R, Mahoney MG, Levy M, Montagutelli X, Ahmad W, Aita VM, Gordon D, Uitto J, Whiting D, Ott J, Fischer S, Gilliam TC, Jahoda CAB, Morris RJ, Panteleyev AA, Nguyen VT, Christiano AM. Desmoglein 4 in hair follicle differentiation and epidermal adhesion: evidence from inherited hypotrichosis and acquired pemphigus vulgaris. *Cell* 2003;113:249–60.
- 67 Rafiq MA, Ansar M, Mahmood S, Haque S, Faiyaz-ul-Haque M, Leal SM, Ahmad W. A recurrent intragenic deletion mutation in DSG4 gene in three Pakistani families with autosomal recessive hypotrichosis. *J Invest Dermatol* 2004;123:247–8.
- 68 Messenger AG, Bazzi H, Parslew R, Shapiro L, Christiano AM. A missense mutation in the cadherin interaction site of the desmoglein 4 gene underlies localized autosomal recessive hypotrichosis. *J Invest Dermatol* 2005;125:1077–9.
- 69 John P, Tariq M, Arshad Rafiq M, Amin-Ud-Din M, Muhammad D, Waheed I, Ansar M, Ahmad W. Recurrent intragenic deletion mutation in desmoglein 4 gene underlies autosomal recessive hypotrichosis in two Pakistani families of Balochi and Sindhi origins. *Arch Dermatol Res* 2006;298:135–7.
- 70 Wajid M, Bazzi H, Rockey J, Lubetkin J, Zlotogorski A, Christiano AM. Localized autosomal recessive hypotrichosis due to a frameshift mutation in the desmoglein 4 gene exhibits extensive phenotypic variability within a Pakistani family. *J Invest Dermatol* 2007;127:1779–82.
- 71 Schaffer JV, Bazzi H, Vitebsky A, Witkiewicz A, Kovich OI, Kamino H, Shapiro LS, Amin SP, Orlow SJ, Christiano AM. Mutations in the desmoglein 4 gene underlie localized autosomal recessive hypotrichosis with monilethrix hairs and congenital scalp erosions. *J Invest Dermatol* 2006;126:1286–91.
- 72 Shimomura Y, Sakamoto F, Kariya N, Matsunaga K, Ito M. Mutations in the desmoglein 4 gene are associated with monilethrix-like congenital hypotrichosis. *J Invest Dermatol* 2006;126:1281–5.
- 73 Zlotogorski A, Marek D, Horev L, Abu A, Ben-Amitai D, Gerad L, Ingber A, Frydman M, Reznik-Wolf H, Vardy DA, Pras E. An autosomal recessive form of monilethrix is caused by mutations in DSG4: clinical overlap with localized autosomal recessive hypotrichosis. *J Invest Dermatol* 2006;126:1292–6.
- 74 Farooq M, Ito M, Naito M, Shimomura Y. A case of monilethrix caused by novel compound heterozygous mutations in the desmoglein 4 (DSG4) gene. *Br J Dermatol* 2011;165:425–31.
- 75 Kato M, Shimizu A, Yokoyama Y, Kaira K, Shimomura Y, Ishida-Yamamoto A, Kamei K, Tokunaga F, Ishikawa O. An autosomal recessive mutation of DSG4 causes monilethrix through the ER stress response. *J Invest Dermatol* 2015;135:1253–60.
- 76 Simpson MA, Mansour S, Ahnood D, Kalidas K, Patton MA, McKenna WJ, Behr ER, Crosby AH. Homozygous mutation of desmocollin-2 in arrhythmic right ventricular cardiomyopathy with mild palmoplantar keratoderma and woolly hair. *Cardiology* 2009;113:28–34.
- 77 Ayub M, Basit S, Jelani M, Ur Rehman F, Iqbal M, Yasinzai M, Ahmad W. A homozygous nonsense mutation in the human desmocollin-3 (DSC3) gene underlies hereditary hypotrichosis and recurrent skin vesicles. *Am J Hum Genet* 2009;85:515–20.
- 78 Dávalos NO, García-Vargas A, Pforr J, Dávalos IP, Picos-Cárdenas VJ, García-Cruz D, Kruse R, Figuera LE, Nöthen MM, Betz RC. A non-sense mutation in the corneodesmosin gene in a Mexican family with hypotrichosis simplex of the scalp. *Br J Dermatol* 2005;153:1216–19.
- 79 Huang XS, Jiang HQ, Quan QL. Clinical investigation of a Chinese family with hypotrichosis simplex of the scalp and mutational analysis of CDSN gene. *Zhonghua Yi Xue Yi Chuan Xue Za Zhi* 2012;29:452–4.
- 80 Oji V, Eckl K-M, Aufenvenne K, Nätebus M, Tarinski T, Ackermann K, Seller N, Metzke D, Nürnberg G, Fölster-Holst R, Schäfer-Korting M, Hausser I, Traupe H, Hennies HC. Loss of corneodesmosin leads to severe skin barrier defect, pruritus, and atopy: unraveling the peeling skin disease. *Am J Hum Genet* 2010;87:274–81.
- 81 Israeli S, Zamir H, Sarig O, Bergman R, Sprecher E. Inflammatory peeling skin syndrome caused by a mutation in CDSN encoding corneodesmosin. *J Invest Dermatol* 2011;131:779–81.
- 82 Telem DF, Israeli S, Sarig O, Sprecher E. Inflammatory peeling skin syndrome caused by a novel mutation in CDSN. *Arch Dermatol Res* 2012;304:251–5.
- 83 Mallet A, Kypriotou M, George K, Leclerc E, Rivero D, Mazereeuw-Hautier J, Serre G, Huber M, Jonca N, Hohl D. Identification of the first nonsense CDSN mutation with expression of a truncated protein causing peeling skin syndrome type B. *Br J Dermatol* 2013;169:1322–5.
- 84 Ishida-Yamamoto A, Furio L, Igawa S, Honma M, Tron E, Malan V, Murakami M, Hovnanian A. Inflammatory peeling skin syndrome caused by homozygous genomic deletion in the PSORS1 region encompassing the CDSN gene. *Exp Dermatol* 2014;23:60–3.
- 85 Teye K, Hamada T, Krol RP, Numata S, Ishii N, Matsuda M, Ohata C, Furumura M, Hashimoto T. Homozygous deletion of six genes including corneodesmosin on chromosome 6p21.3 is associated with generalized peeling skin disease. *J Dermatol Sci* 2014;75:36–42.