

# Genotype–phenotype correlation in 21 patients with Wolf–Hirschhorn syndrome using high resolution array comparative genome hybridisation (CGH)

N M C Maas,<sup>1</sup> G Van Buggenhout,<sup>1</sup> F Hannes,<sup>1</sup> B Thienpont,<sup>1</sup> D Sanlaville,<sup>2</sup> K Kok,<sup>3</sup> A Midro,<sup>4</sup> J Andrieux,<sup>5</sup> B-M Anderlid,<sup>6</sup> J Schoumans,<sup>6</sup> R Hordijk,<sup>3</sup> K Devriendt,<sup>1</sup> J-P Fryns,<sup>1</sup> J R Vermeesch<sup>1</sup>

<sup>1</sup> Center for Human Genetics, University Hospital, Catholic University of Leuven, Leuven, Belgium; <sup>2</sup> Department of Genetics, Hôpital Necker-Enfants Malades, Assistance Publique-Hôpitaux de Paris, Paris, France; <sup>3</sup> Department of Medical Genetics, University Medical Center Groningen, Groningen, The Netherlands; <sup>4</sup> Department of Clinical Genetics of the Medical University Białystok, Poland; <sup>5</sup> St Vincent Hospital, Lille, France; <sup>6</sup> Department of Molecular Medicine, Karolinska Hospital, Stockholm, Sweden

Correspondence to: J R Vermeesch, Center for Human Genetics, Herestraat 49, 3000 Leuven, Belgium; Joris.Vermeesch@uz.kuleuven.ac.be

Received 6 July 2007

Revised 21 August 2007

Accepted 23 August 2007

Published Online First

14 September 2007

## ABSTRACT

**Background:** The Wolf-Hirschhorn syndrome (WHS) is usually caused by terminal deletions of the short arm of chromosome 4 and is phenotypically defined by growth and mental retardation, seizures, and specific craniofacial manifestations. Large variation is observed in phenotypic expression of these features. In order to compare the phenotype with the genotype, we localised the breakpoints of the 4pter aberrations using a chromosome 4 specific tiling BAC/PAC array.

**Methods:** In total, DNA from 21 patients was analysed, of which 8 had a cytogenetic visible and 13 a submicroscopic deletion.

**Results and conclusion:** In addition to classical terminal deletions sized between 1.9 and 30 Mb, we observed the smallest terminal deletion (1.4 Mb) ever reported in a patient with mild WHS stigmata. In addition, we identified and mapped interstitial deletions in four patients. This study positions the genes causing microcephaly, intra-uterine and postnatal growth retardation between 0.3 and 1.4 Mb and further refines the regions causing congenital heart disease, cleft lip and/or palate, oligodontia, and hypospadias.

Wolf–Hirschhorn syndrome (WHS), first described by Wolf *et al*<sup>1</sup> and Hirschhorn *et al*,<sup>2</sup> is usually caused by a partial deletion of the short arm of chromosome 4. It is a well known syndrome with growth and mental retardation, microcephaly, seizures, “Greek helmet” facies (fig 1), and major malformations such as cleft lip and/or palate (CL/P), coloboma of the eye, congenital heart defects (CHD), and hypospadias. Large variation is observed in phenotypic expression. These features, especially the facial appearance, change with ageing.<sup>3–7</sup> The Pitt–Roger–Danks syndrome was described as the milder end of the clinical spectrum of the WHS.<sup>8</sup> Although WHS affects around 1 per 50 000 births, it is suspected that the syndrome is more frequent, because not all patients can be diagnosed with a standard chromosomal investigation.<sup>8</sup> In our experience, the incidence of WHS patients is similar to the incidence of Angelman syndrome patients—about 1 per 20 000 births. In case of a clinical suspicion of WHS in a patient with normal chromosomes, additional fluorescence in situ hybridisation (FISH) studies of the subtelomeres and the WHS critical region (WHSCR) are usually performed.

Different genes probably play an important role in the complex phenotype of WHS. One approach

to understand the role of different genes is to compare the phenotypes of patients with differently sized deletions and correlating the genotype with the phenotype.<sup>5–9–14</sup> Earlier genotype–phenotype correlation studies identified a WHSCR of approximately 165 kb. This WHSCR covers the entire WHS candidate gene 2 (*WHSC2*), and part of the WHS candidate gene 1 (*WHSC1*).<sup>15–16</sup> In a recent study, this 165 kb WHSCR was not deleted in one patient with a typical WHS face, which prompted the investigators to assign a new critical region of WHS, “*WHSCR2*”. This region includes the *LETM1* and partially the *WHSC1*, but not the *WHSC2* gene.<sup>11</sup> We reported on five mild WHS patients with small deletions of chromosome 4p covering or flanking the WHSCR, which also pinpointed the *WHSC1* as the main candidate for causing the facial WHS appearance.<sup>12</sup>

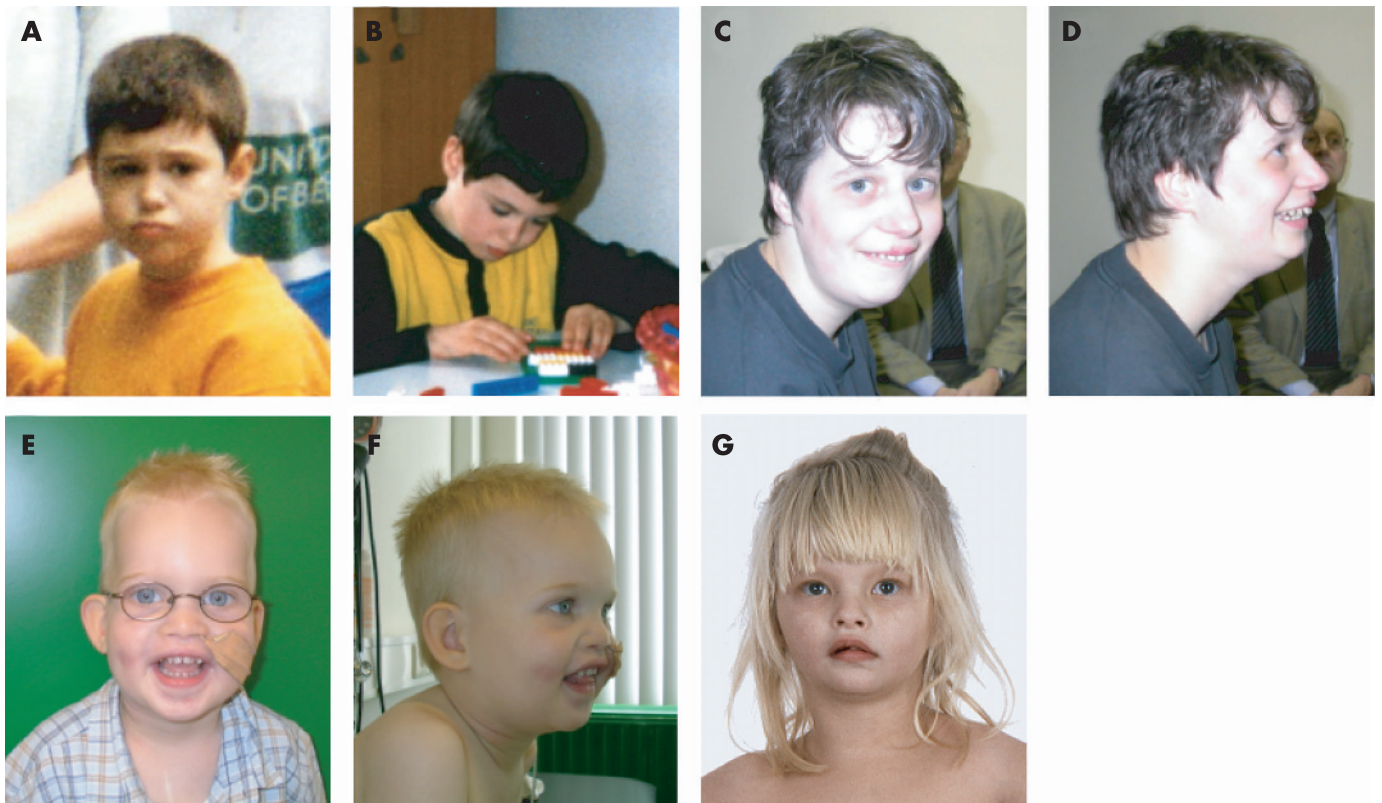Genotype–phenotype correlation studies suggest that hemizygoty of genes other than *WHSC1* in the region contribute to some of the phenotypic aspects. An overview of the genes in the region and their potential contribution to the WHS phenotype was described before.<sup>14</sup> CL/P, CHD, renal abnormalities and severe mental retardation are rare in patients with a small terminal microdeletion, but are common in patients with a larger deletion extending to proximal of 4.4 Mb.<sup>10</sup> However, which of these genes is responsible for which phenotype remains unknown, with the exception of *LETM1* which is the most likely candidate gene for epilepsy in WHS patients.<sup>17</sup>

In order to advance phenotype–genotype correlation efforts, we present genotype–phenotype correlations of eight previously reported and 13 new patients with WHS phenotypic features, and characterised the location and size of the deletions by full tiling chromosome 4 BAC array comparative genome hybridisation (CGH) for all 21 patients. Previous genotype–phenotype correlations of this region have been hampered by the presence of other imbalances in part of the WHS patients which likely confused some of the correlations. In this study, only patients with pure 4p deletion were included, which enables us to further refine the 4p phenotypic map.

## PATIENTS AND METHODS

### Patients

All 21 patients were diagnosed and clinically examined by clinical geneticists in Brussels and



**Figure 1** Facial features of five patients with Wolf-Hirschhorn syndrome (WHS). (A, B) Patient 1 from frontal and side. (C, D) Patient 3 from frontal and side. (E, F) Patient 17 from frontal and side. (G) Patient 15 from frontal. Parental/guardian informed consent was obtained for publication of this figure

Leuven (Belgium), Groningen (The Netherlands), Stockholm (Sweden), and Paris and Lille (France). A personal and family history was obtained from each patient. Most patients were regularly re-evaluated during several years and follow up data could be recorded. A summary of the clinical features for each patient is provided in tables 1 and 2. Patient 5, 6, 8–11, 20 and 21 have been described elsewhere.<sup>12 18–22</sup>

### Cytogenetic analysis

Karyotyping was performed on metaphase spreads prepared from peripheral blood lymphocytes by routine standard cytogenetic procedures.<sup>23</sup>

### Fluorescence in situ hybridisation (FISH)

The deletion for all but two patients was confirmed using the commercial LSI WHS region/CEP 4 control (dual colour) (Abbott Inc, Downers Grove, Illinois, USA). The WHSCR probe covering the entire 165 kb WHSCR between loci D4S166 and D4S3327 (Cytocell Technologies Ltd, Oxford, UK) was used to analyse the metaphase spreads of patient 2. The metaphase spreads of patient 1 have been tested with probe D4S96 (Oncor, Parsippany, New Jersey, USA) located at ~1.2 Mb from the telomere. Locus specific BAC or PACs were Spectrum Orange labelled as described before.<sup>23</sup>

### Array CGH

Genome wide array CGH at 1 Mb resolution was performed as described before.<sup>23</sup> A chromosome 4 tiling BAC array containing 1903 targets was generated as described elsewhere. The DNA from these BAC and PAC targets was obtained from CHORI.<sup>24</sup>

Cy5 labelled patient DNA was co-hybridised versus Cy3 labelled reference DNA of a healthy individual. The fluorescence intensities measured were first background subtracted. Normalisation was performed by dividing each  $\log_2$  transformed intensity ratio by the mean of the  $\log_2$  transformed intensity ratios of all targets derived from the long arm of chromosome 4. In about one third of the hybridisations, an additional 2D normalisation was performed using Bioconductor (<http://www.bioconductor.org>).<sup>25 26</sup> If successive clones have intensity values below  $4 \times$  SD of all intensity ratios, the region is considered deleted. Hybridisation efficiencies of the chromosome 4 tiling array were around 97%. The average standard deviation of the  $\log_2$  intensity ratio per experiment was 0.08. Graphs of the array-CGH analysis of DNA from a patient with a small terminal and a cytogenetically visible interstitial deletion are provided in fig 2.

## RESULTS

### Genotype-phenotype correlation

In this study, we aim to correlate the WHS phenotypes with 4p deletion sizes and therefore excluded patients carrying unbalanced translocations or other chromosomal rearrangements which may influence the phenotypic features.<sup>15</sup> About one of five WHS patients were a carrier of a cryptic translocation. The presence of unbalanced translocations was excluded by subtelomeric FISH for patients 5, 6, 10, 11, and 21,<sup>12 20</sup> and both subtelomeric and interstitial chromosomal rearrangements were excluded by 1 Mb array CGH in the other patients. Thus, only those patients with pure 4p deletions were retained in this study. Subsequently, DNA from patients was hybridised on a chromosome 4 tiling array.

**Table 1** Clinical findings in nine Wolf-Hirschhorn syndrome (WHS) patients with de novo cytogenetically visible deletions

Case	14	15	16	17	18	19	20	21	Total
Sex	F	F	M	M	M	F	F	F	5/3
<b>Facial appearance</b>									
Greek warrior helmet facies	+	+	+	-	+	+	+	+	7/8
Hypertelorism	+	+	+	+	+	+	+	+	8/8
Prominent glabella	+	+	+	-	+	+	+	+	7/8
High forehead	+	+	+	+	+	+	+	+	8/8
Epicanthus	+	+	-	-	+	-	+	+	5/8
Broad nose	-	-	+	+	+	+	+	+	6/8
Beaked nose	-	-	-	-	+	+	+	+	4/8
Short philtrum	+	+	+	+	+	+	+	+	8/8
Oligodontia	NI	+	NI	-	NI	NI	Too young	Too young	1/2
Micrognathia	+	+	+	+	+	+	+	+	8/8
Downturned shape of the mouth	+	+	+	+	+	+	+	+	8/8
Cleft lip/palate	-/-	-/-	-/-	-/-	-/-	-/-	-/+	-/+	2/8
Colobomata of iris	-	-	+	-	-	-	+	+	3/8
Narrow lacrimal ducts	NI	-	NI	-	+	NI	NI	+	2/4
Strabismus	+	-	+	+	+	+	-	NI	5/7
Dysplastic ears	+	-	+	+	+	+	+	+	7/8
Preauricular tag/pit	-	-	-	-	+	-	-	+	2/8
<b>Birth</b>									
Gestational weeks at birth (weeks, days)	33	38	38	40, 2	38	37	41, 5	37, 2	38*
Weight (g)	1180 (<P10)	1630 (<P10)	1900 (<P10)	3660 (P75-P90)	1930 (<P10)	1500 (<P10)	2610 (<P10)	1550 (<P10)	1995*
Length (cm)	39 (<P10)	42 (<P10)	49 (P50-P75)	52 (P50-P75)	47.5 (P25-P50)	NI	48 (P10-P25)	42 (<P10)	46*
IUGR	+	+	+	-	+	+	+	+	7/8
OFc (cm)	27 (<P10)	30.5 (<P10)	30 (<P10)	4 weeks: 36 (P10-P25)	34.5 (P75-P90)	NI	NI	NI	30.5*
Microcephaly at birth	+	+	+	-	-	+	NI	+	5/7
<b>Postnatal examination</b>									
Age at examination (years, months)	6	12	7	3, 6	5	50	1, 6	0, 2	
Height (cm)	89 (<P3)	142 (P10-P25)	<P3	9 (-1SD)	<P3	120 (<P3)	72.5 (<P3)	47.5 (<P3)	
Weight (kg)	8.0 (<P3)	30 (P10)	<P3	12.6 (-2SD)	<P3	25 (<P3)	6.9 (<P3)	2.5 (<P3)	
OFc (cm)/microcephaly (+/-)	44.2 (<P3)	48 (<P3)	+	47.5 (-2SD)	43 (<P3)	46 (<P3)	42.2 (<P3)	35 (<P3)	
Mental retardation	Severe	Severe	+	10.74	Severe	Profound	Profound	Profound	
Sitting without support (years, months)	3, 6	1, 5	3, 6	1, 6	-	-	-	-	4/8
Walking without support (years, months)	-	3, 5	6	3, 6	-	-	-	-	3/8
Speech (years, months)	-	-	7	1, 5	-	-	-	-	2/8
Hypotonia	+	-	+	+	+	+	-	+	6/8
Seizures	+	+	+	-	+	+	+	+	7/8
Congenital heart defects	+	-	-	+	+	-	-	-	3/8
Clubbing of fingers/toes	-	-	-	+	+	-	-	-	0/8
	(ASDII, Pst)		(AVSD)*		(ASDII, Pst)				

Continued

Table 1 Continued

Case	14	15	16	17	18	19	20	21	Total
Scoliosis	-	-	-	-	+	+	-	-	2/8
Club feet	-	-	-	-	-	+	+	-	2/8
Renal anomalies	Renal reflux	-	-	-	NI	NI	-	-	1/6
Genital anomalies	-	NI	Hypospadias	++†	Hypospadias	-	+	Ventrally spaced anus	5/7
Sacral dimple	+	NI	NI	+	+	+	+	+	6/6
Deletion (start–end in Mb)	8.8	1.8–10.1	10.9	2.7–14.8	14.8	16.5	19.5	37	
Diagnosis by	G-banding	1 Mb array (spectral genomics)	G-banding	G-banding	G-banding	G-banding	G-banding	G-banding	
Subtelomeric screening by	1 Mb array	1 Mb array	1 Mb array	Interstitial deletion	1 Mb array	1 Mb array	FISH subtel	1 Mb array	
Last normal clone (interstitial) (Mb)		RP11-138D6 (1.7–1.9)		RP11-444J4 (2.6–2.7)					
First deleted clone (interstitial) (Mb)		RP11-1170P16 (1.8–1.9)		RP11-372F2 (2.9–3.1)					
Last deleted clone (Mb)	RP11-689P11 (8.5–8.7)	RP11-572M24 (10.1–10.2)	RP11-518L6 (10.9–11.1)	RP11-804D20 (14.7–14.9)	RP11-558F7 (14.6–14.8)	RP11-142E22 (16.5–16.7)	RP11-107E4 (19.4–19.6)	RP11-759E10 (37.3–37.6)	
First normal clone (Mb)	RP11-637J21 (8.6–8.8)	RP11-61G19 (10.2–10.4)	RP11-775H15 (11.0–11.2)	RP11-161H8 (14.8–15.0)	RP11-804D20 (14.7–14.9)	RP11-714L13 (16.6–16.8)	RP11-5N10 (19.5–19.7)	RP11-177C12 (37.5–37.7)	
Cytogenetic band	4p16.1	4p16:1p16.3	4p16.1	4p15.33p16.3	4p15.33	4p15.32	4p15.31	4p14	

ASD: atrial septal defect; F: female; IUGR, intrauterine growth retardation; M: male; NI, not investigated; OFC, occipitofrontal circumference; Pst, pulmonic stenosis; VSD, ventricular septal defect.

\*Average; †see clinical description.

## DISCUSSION

Genotype–phenotype correlation studies may enable the identification of the role of the different 4p genes in the aetiology of WHS. However, several issues remain to be resolved. The number of patients analysed is still limited and the resolution at

Of eight patients with cytogenetically visible terminal 4p deletions, six carried a terminal 4p deletion. Patient 17 carried an interstitial deletion 1 Mb upstream of the *WHSCR1* from 2.7 to 14.8 Mb (fig 2B), and patient 15 had an interstitial deletion spanning between 1.8 and 10.1 Mb from the telomere. An overview of the genotypes and phenotypes of the eight patients is shown in table 1 and fig 3A. Hypertelorism, prominent glabella, high forehead, short philtrum, typical down turned or carp shaped mouth, and microcephaly were present in all patients. The typical facial features, intrauterine growth retardation (IUGR) and seizures were present in all patients except for patient 17 (2.7 to 14.8 Mb interstitial deletion). In two of these eight patients a CL/P was observed (patient 20 and 21), with terminal deletions of 19.5 Mb and 37 Mb, respectively. Strabismus was present in five of the seven investigated patients (not in patient 15 (1.8 to 10.1 Mb deletion) and 20 (0 to 19.5 Mb deletion)). Colobomata of the iris were observed in three patients with deletions of at least 10.9 Mb from the telomere. Two patients (patients 18 and 21 with, respectively, a 14.8 and 37 Mb terminal deletion) were found to have narrow lacrimal ducts. A pre-auricular tag or pit was observed in patients with deletions of 14.8 Mb and larger. All patients had mental, postnatal growth, and psychomotor retardation. Of six patients who underwent renal ultrasound, a renal defect was only found in one patient (patient 14 with an 8.8 Mb deletion). Fifteen of the 17 investigated patients had sacral dimples. All three boys with a large deletion presented with genital defects. Patients 16 and 18 had hypospadias (10.9 and 14.8 Mb terminal deletions), and patient 17 had a normal migrated left testis and a non-descended right testis (2.7 to 14.8 Mb interstitial deletion). Hypotonia was present in six of eight individuals except patient 15 and 20 (1.8–10.1 and 0–19.5 Mb deletion).

In 13 patients, a submicroscopic deletion was initially detected by FISH. In 11 of them, the deletion was observed by FISH using the locus specific probe detecting the *WHSCR1* deletion. However, in patient 1, the deletion was detected using the Oncor WHS probe located distally from *WHSCR1*. Subsequently, array-CGH was performed to determine the deletion boundaries. This patient had a 1.4 Mb terminal deletion not including the *WHSCR1*, confirmed by FISH with the flanking clones RP11-1244E8 (1.35 to 1.42 Mb, deleted) and RP11-1398P2 (1.46 to 1.61 Mb, normal) and the deleted telomeric clone CTC-36P21. In patient 2, FISH using the Cytocell WHS probe presented a weak signal in one chromosome 4 and a strong signal in the other chromosome 4 in all metaphases, suggesting a partial deletion. Array-CGH pinpointed the breakpoint between RP11-21I14 (1.91 to 2.10 Mb, deleted) and RP11-318G6 (2.00 to 2.19 Mb, normal) (Ensembl release 42, December 2006). In two patients (patient 6 and 10), small interstitial deletions were observed. An overview of the genotype–phenotype correlation of these 13 patients is shown in table 2 and fig 3B. Patients with deletions of the *WHSCR1* all present with the characteristic facial features, except for patient 3. Patient 1 with the 1.4 Mb terminal deletion not involving the *WHSCR1* had mild clinical stigmata and no typical WHS face. Patient 10 with the 1.8 to 3.6 Mb interstitial deletion presented with the typical WHS face, but lacked most other WHS stigmata.

Table 2 Clinical findings in 13 Wolf-Hirschhorn syndrome (WHS) patients with de novo microdeletions

Case:	1	2	3	4	5	6	7	8	9	10	11	12	13
<b>Sex</b>	M	M	F	M	F	M	M	F	F	M	F	M	M
<b>Facial appearance</b>													
Greek warrior helmet facies	-	+	-	+	+	+	-	+	+	+	+	+	+
Hypertelorism	-	+	+	NI	NI	-	+	+	+	+	+	-	+
Prominent glabella	-	+	-	+	NI	-	+	+	NI	+	+	-	+
High forehead	-	+	+	NI	NI	+	+	+	NI	+	+	+	+
Epicanthus	NI	NI	-	-	NI	-	-	+	NI	-	-	+	-
Broad nose	-	+	+	NI	NI	-	+	+	+	+	+	-	-
Beaked nose	-	+	+	NI	NI	-	-	-	NI	+	+	-	+
Short philtrum	-	+	+	NI	+	-	+	+	NI	+	+	-	+
Oligodontia	NI	-	-	NI	NI	+	+	+	NI	NI	+	NI	+
Micrognathia	-	+	-	+	+	-	+	-	NI	+	-	+	+
Downturned shape of the mouth	-	+	-	+	NI	-	+	+	NI	-	+	+	-
Cleft lip/palate	-/-	-/-	-/-	-/-	NI	-/-	-/-	-/-	NI	-/-	-/+	-/-	-/-
Colobomata of iris	-	-	-	-	-	-	-	-	NI	-	-	-	-
Narrow lacrimal ducts	NI	-	-	NI	NI	-	NI	-	NI	-	NI	NI	-
Strabism	-	+	-	-	-	-	+	+	NI	-	-	+	-
Dysplastic ears	-	+	+	+	+	+	+	+	NI	-	+	+	+
Preauricular tag/pit	-	-	-	-	-	-	-	-	NI	-	-	-	-
<b>Birth</b>													
Gestational weeks at birth	40	36	NI	39	37	38	32	37	40	42	42	34	40
Weight (g)	2080 (<P3)	1570 (<P3)	2640	2270 (<P3)	2050 (P3-P10)	2330 (P3-P10)	1800 (P50-P75)	2460 (P25)	2010 (<P3)	3250 (P50)	1900 (P3-P10)	2650 (P75-P90)	1900 (<P3)
Length (cm)	47 (P10-P25)	NI	NI	47.5 (P25)	44 (P10-P25)	44 (<P10)	42 (P50)	46 (P25)	44 (<P10)	50 (P50-P75)	45 (<P10)	49 (P90)	NI
IUGR	+	+	+	+	+	+	+	+	+	-	+	-	+
OFC (cm)	NI	NI	NI	33 (P25-P50)	29 (<P10)	0 y1 m: 34 cm (<P3)	30 (P75-P90)	32 (P25)	31 (<P10)	36.2 (>P90)	30 (<P10)	NI	NI
Microcephaly at birth	NI	NI	NI	-	+	+	-	-	+	-	+	NI	NI
Neonatal feeding difficulties	NI	NI	NI	NI	NI	NI	+	NI	NI	NI	NI	NI	+
<b>Postnatal examination</b>													
Age at examination (year, month)	11, 8	2, 4	23	12	16	13	13	3, 6	12	13, 6	14	29	5, 6
Length (cm)/short stature (+/-)	+	87 (P10-P25)	NI	151 (P50-P75)	+	172 (>P97)	129 (<P3)	+	128 (<P3)	155 (P25-P50)	149 (<P3)	153 (<P3)	93 (<P3)
Weight (kg)/low weight (+/-)	+	9, 2	-	31 (P10-P25)	+	41, 3 (P25-P50)	21 (<P3)	-2SD	23 (<P3)	32, 1 (P3-P10)	36, 7 (<P3)	-	11, 5 (<P3)
OFC (cm)/microcephaly (+/-)	+	46.3 (<P3)	+	NI	+	50 (<P3)	48, 5 (<P3)	-2SD	49 (<P3)	53.4 (P25)	11 y: 47.3 (<P3)	52 (<P3)	44.8 (>P3)
Mental retardation	Moderate	Severe	Severe	Moderate	+	Mild/moderate	Moderate	Severe	Severe	Mild/moderate	Moderate/severe	Severe	Moderate
Sitting without support (year, month)	+	-	NI	0, 1	NI	1, 2	NI	5, 0	+	0, 9	NI	3	+

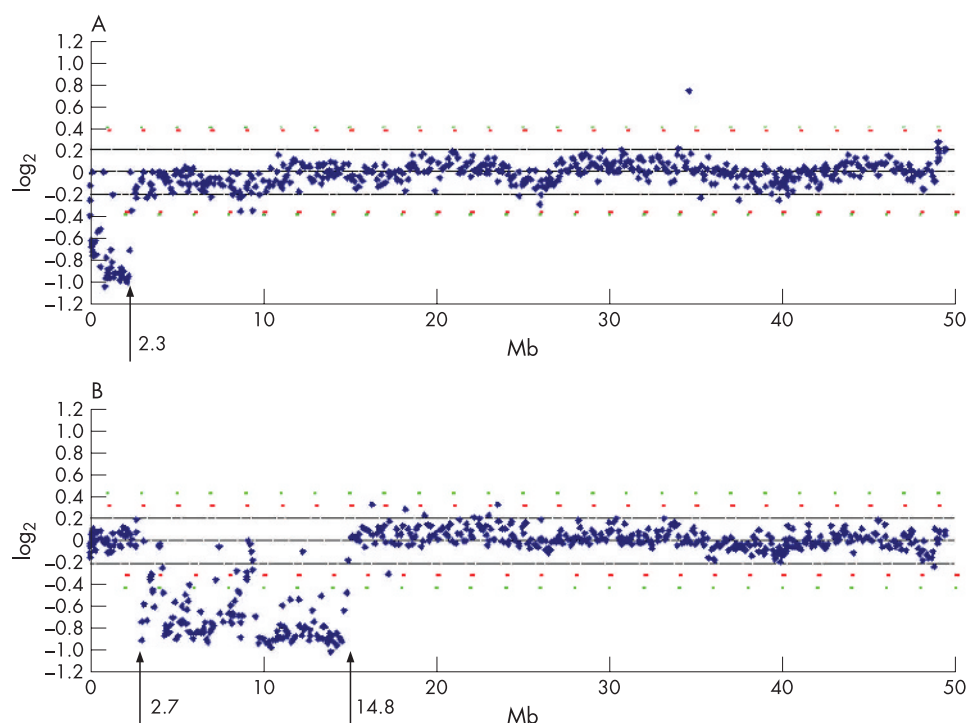
Continued

**Table 2** Continued

Case:	1	2	3	4	5	6	7	8	9	10	11	12	13
Walking without support (year/month)	1, 6	-	NI	2, 1	NI	1, 6	2, 6	-	NI	1, 3	NI	6	1, 2
Speech (year, month)	+	-	-	5, 5	NI	4	+	-	-	+	4	-	+
Hypotonia	-	-	+	+	+	+	+	+	NI	+	NI	-	-
Seizures	+	+	+	+	+	-	+	+	+	-	-	-	-
Deafness	-	-	-	-	NI	-	-	-	+	-	-	-	-
Congenital heart defects	-	+	+	+	+	+	+	-	NI	-	+ Pst	-	-
Clubbing of fingers/toes	-	-	-	-	NI	-	-	-	NI	NI	NI	-	-
Scoliosis/hyperk	-	-	+	NI	-	+	+	-	NI	+	+	-	-
Club feet	-	-	+	NI	NI	-	-	-	NI	NI	NI	-	-
Renal anomalies	-	Left sided kidney duplication	-	-	NI	NI	Vesico-urethral reflux	-	NI	NI	NI	NI	2/7
Genital anomalies	-	Hypospadias	-	Hypospadias	NI	Hypospadias	Hypospadias	-	NI	NI	Clitoromegaly	Hypospadias	Hypospadias
Sacral dimple	+	+	+	-	+	+	-	NI	NI	+	+	+	+
Extra	-	Hip dysplasia, nystagmus	-	Scoliosis	-	-	Kyphosis	-	Aphasia hyperactive	Left inguinal hernia	Left diaphragmatic hernia	-	-
<b>Delineation of the deletion</b>													
Deletion (start-end in Mb)	1.4	1.9	2.0	2.2	2.3	1.1-2.5	2.7	2.7	2.7	1.8-3.6	3.7	4.8	5.3
Diagnosis by means of	FISH Oncor probe	FISH Cytocell probe	FISH Vysis probe	FISH Vysis probe	FISH Vysis probe	FISH Vysis probe	FISH Vysis probe	FISH Vysis probe	FISH Vysis probe	FISH Vysis probe	FISH Vysis probe	FISH Vysis probe	FISH Vysis probe
Subtelomeric screening by	1 Mb array	1 Mb array	1 Mb array	1 Mb array	1 Mb array	1 Mb array	1 Mb array	1 Mb array	1 Mb array	1 Mb array	1 Mb array	1 Mb array	1 Mb array
Last normal clone (Mb)	RP11-386115 (1.3-1.4)	RP11-21114 (1.9-2.1)	RP11-318G6 (2.0-2.2)	RP11-440D10 (2.2-2.4)	RP11-478C1 (2.1-2.3)	RP11-478A6 (2.4-2.6)?	RP11-444J4 (2.6-2.7)	RP11-444J4 (2.6-2.7)	RP11-444J4 (2.6-2.7)	RP11-444J4 (2.6-2.7)	RP11-444J4 (2.6-2.7)	RP11-489M13 (4.0-4.2)	RP11-359G4 (4.7-4.9)
First deleted clone (interstitial) (Mb)	RP11-1398P2 (1.5-1.6)	RP11-318G6 (2.0-2.2)	RP11-478C1 (2.1-2.3)	RP11-478A6 (2.4-2.6)?	RP11-503N18 (2.3-2.5)	RP3-474M20 (2.6-2.7)?	RP11-372F2 (2.9-3.1)	RP11-372F2 (2.9-3.1)	RP11-372F2 (2.9-3.1)	RP11-529E10 (3.4-3.6)	RP11-489M13 (4.0-4.2)	RP11-326I19 (4.8-5.0)	CTD-2265H21 (5.3-5.5)
Last deleted clone (Mb)	RP11-386115 (1.3-1.4)	RP11-21114 (1.9-2.1)	RP11-318G6 (2.0-2.2)	RP11-440D10 (2.2-2.4)	RP11-478C1 (2.1-2.3)	RP11-478A6 (2.4-2.6)?	RP11-444J4 (2.6-2.7)	RP11-444J4 (2.6-2.7)	RP11-444J4 (2.6-2.7)	RP11-444J4 (2.6-2.7)	RP3-513G18 (3.6-3.7)	RP11-359G4 (4.7-4.9)	RP11-326I19 (4.8-5.0)
Chr. 4 band	4p16.3	4p16.3	4p16.3	4p16.3	4p16.3	4p16.3p16.3	4p16.3	4p16.3	4p16.3	4p16.3p16.3	4p16.3	4p16.2	4p16.2

ASD, atrial septal defect; F, female; FISH, fluorescence in situ hybridisation; IUGR, intrauterine growth retardation; M, male; NI, not investigated; OFC, occipitofrontal circumference; Pst, pulmonic stenosis; VSD, ventricular septal defect. \*Average.

**Figure 2** Results of the array CGH analysis of two patients. The Y axis represents the  $\log_2$  of the intensity ratios of the combined dye swap experiments of patient versus control DNA. In the X axis the spotted clones are ordered from the 4p telomere to the centromere. The distance from the 4p telomere is indicated in Mb. The arrows indicate the location of the breakpoints and the distance from the telomere is indicated. (A) DNA from a patient with a small terminal deletion. (B) DNA from a patient with a cytogenetically visible interstitial deletion.



which the location of the breakpoints has thus far been analysed is low. Second, most genotype–phenotype correlation studies are derived from patients with large cytogenetically visible deletions spanning several Mb. Third, since several of the clinical features of this syndrome have considerable variable expressivity or penetrance, the phenotypic characterisation of many more WHS patients will be required to pinpoint the genes involved in these more rare aspects of the WHS phenotype. Fourth, the role of position effects due to the relocation of the telomeres is unknown. Finally, since WHS is a contiguous gene syndrome, some of the features seen in WHS could result from haploinsufficiency of more than one gene in the region. Unravelling the contribution of each of the genes in the region to these multigenic phenotypes provides a new challenge for geneticists.

This report presents the largest genotype–phenotype correlation analysis of WHS patients thus far. Using a chromosome 4 tiling path array, both interstitial and terminal 4p deletion breakpoints were fine mapped. In addition to the classical terminal deletions, sized between 1.9 and 30 Mb, we identified a 1.4 Mb terminal deletion, the smallest deletion ever to be reported in a patient with WHS phenotypic features. In addition, we identified and mapped four interstitial deletions. Both the patients lacking all classic WHS features and the atypical deletions advanced the dissection of the molecular features leading to the different WHS characteristics.

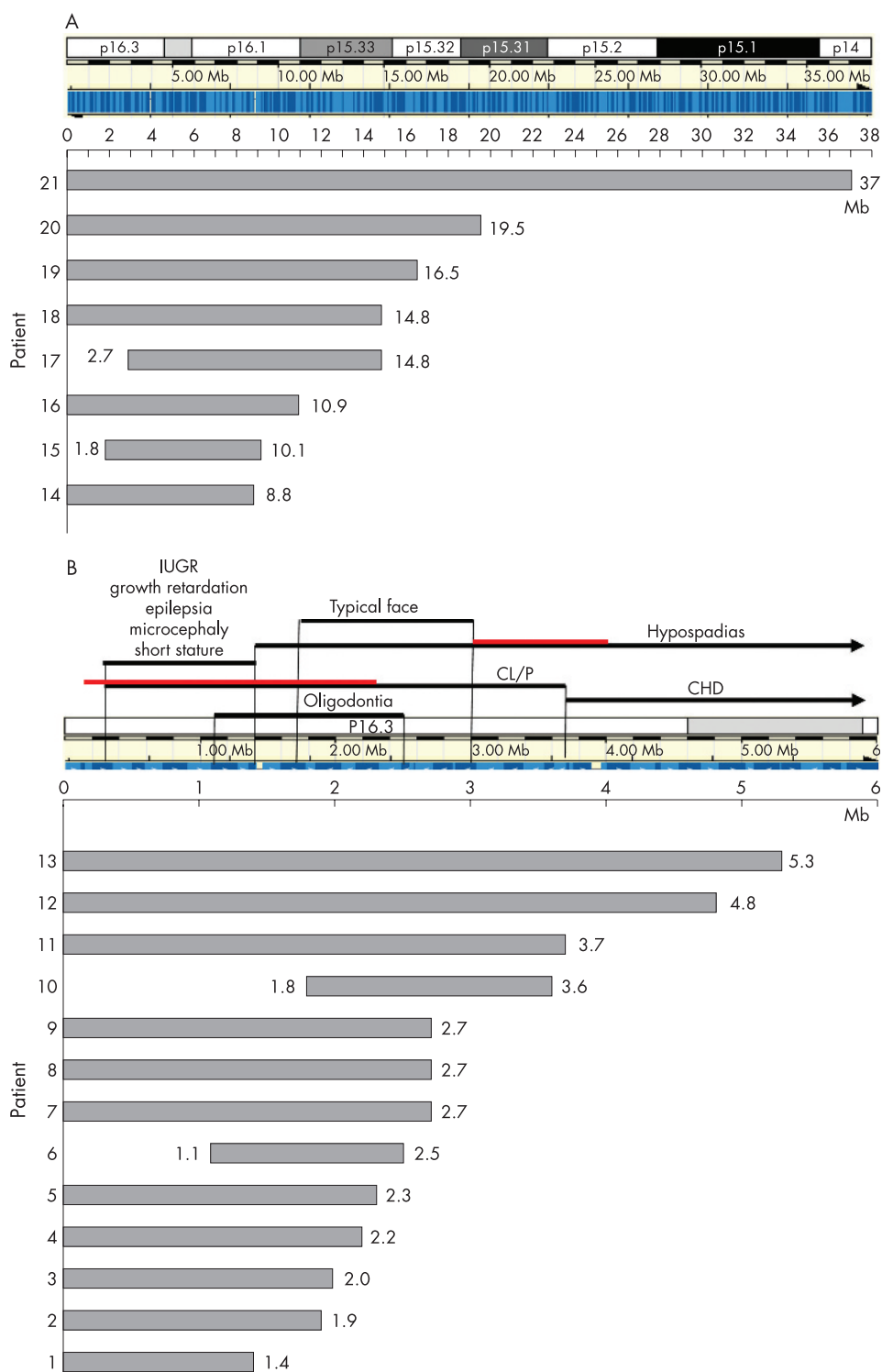
The main characteristic of WHS is the typical face, usually referred to as a “Greek warrior helmet face”. Previous studies hypothesised hemizygosity of the *WHSC1* as the most likely cause of the facial phenotype.<sup>10 12 27</sup> This notion was confirmed by the present study. All, except in one patient with a *WHSC1* deletion, did have the typical facial features. The patient with the *WHSC1* deletion but without the typical face is 23 years old. Because of advancing age the facial features could have coarsened over time (patient 3, fig 1C,D).<sup>7 28</sup> One other patient (patient 7) has partial facial phenotypic features but was not considered to have the “Greek warrior helmet”. The two

patients in this study without the facial WHS features do not have a deletion of *WHSC1*: one patient had only a 1.4 Mb terminal deletion not covering the *WHSC1* (patient 1, fig 1A,B), while another patient had a large interstitial deletion upstream of the *WHSC1* (patient 17, fig 1E,F).

The molecular features of *WHSC1* suggest that the gene might function as a chromatin remodelling enzyme because SET domains have been shown to function as histone methylases.<sup>29</sup> A deficiency in chromatin remodelling could deregulate the expression of a variety of genes and hence lead to pleiotropic effects. Recent studies indicated that haploinsufficiency of other chromatin remodelling enzymes cause syndromic phenotypes such as the Chromodomain helicase DNA-binding protein 7 (*CHD7*) gene, causing the CHARGE (Coloboma, Heart anomaly, Choanal atresia, Retardation, Genital and Ear Anomalies) syndrome,<sup>30</sup> the Nipped-B-like (*NIPBL*) gene, causing the Cornelia de Lange syndrome,<sup>31</sup> and heterozygous mutations in the V-ha-ras Harvey rat sarcoma viral oncogene homologue (*HRAS*) gene, causing the Costello syndrome.<sup>32</sup> Because of this possibility, we sequenced the *WHSC1* gene in five WHS patients without 4p deletions (data not shown). Intriguingly, no mutations were detected in this nor in previous studies.<sup>29</sup> Either mutations elsewhere in the genome can cause phenocopies of the WHS, or *WHSC1* is the wrong target gene and another gene in the region is key for the phenotype.

Patient 17, a boy with a large interstitial deletion ranging from 2.7 to 14.8 Mb, has normal growth parameters, he had no seizures, and mental delay was mild with an IQ of 74. Sitting and walking without support and speech were only mildly delayed compared to the other patients with large deletions. In contrast, all patients with large 4pter deletions, including our six patients with large terminal deletions sized between 8.8 and 37 Mb, present with pre- and postnatal growth retardation, the typical face, seizures, microcephaly, severe to profound mental and psychomotor retardation and muscular hypotonia (the latter except patient 20). Hence, haploinsufficiency of genes in the 2.7 Mb 4pter region causes these WHS main features.

**Figure 3** (A) Results of the detected deletions using the full tiling array CGH of chromosome 4 in eight Wolf–Hirschhorn syndrome (WHS) patients with microscopically visible deletions. The bars show the sizes of the deletions. (B) Results of the detected deletions using the full tiling array CGH of chromosome 4 in 13 WHS patients with submicroscopic deletions. The bars show the sizes of the deletions. The thick black bars show the locations of the candidate regions for each phenotypic feature. The red bars show the locations of the critical regions for hypospadias and CL/P defined by Estabrooks *et al.*<sup>34</sup>



Not only patient 17 (2.7–14.8 Mb deletion), but also patient 10 with an interstitial deletion (1.8–3.6 Mb deletion) has normal growth parameters. A patient with a normal height and a 191 kb deletion encompassing the *WHSC1* and *WHSC2* genes was described.<sup>16</sup> In contrast, the patient with a 1.4 Mb terminal deletion did present with short stature and IUGR. Therefore, this study locates a short stature candidate region in the terminal 1.4 Mb.

In our previous study, a healthy female with multiple miscarriages carried a 0.3 Mb terminal deletion.<sup>12</sup> Therefore, the 0.3 Mb terminal region is not a candidate region for the genotypic

map. Previously, we speculated that the WHS associated microcephaly might be the result of a contiguous deletion involving at least two genes, one located in a 1.8 Mb terminal region and one between 2.2–2.5 Mb. This hypothesis resulted from patients carrying a 1.9 and 2.2 terminal deletion without microcephaly. This latter observation may also result from incomplete penetrance or genetic modifiers. The microcephaly in the patient with a 1.4 Mb terminal deletion as well as in the other three investigated patients with deletion sizes up to 2.3 Mb is, however, more consistent with a gene localised in this terminal 1.4 Mb region.



Hemizyosity of *LETM1*, a ubiquitous Ca<sup>2+</sup> binding protein involved in Ca<sup>2+</sup> homeostasis, located at 1.8 Mb from the 4p telomere, has been suggested to cause seizures.<sup>11–38</sup> However, the patient with an interstitial deletion encompassing *LETM1* (patient 6) did not present with seizures, while the patient with the 1.4 Mb terminal deletion did present with seizures. Therefore, another gene in this terminal region may cause the epilepsy.

Besides these main characteristics features, WHS is characterised by several minor features. Oligodontia occurred in six of the nine investigated WHS patients in the present study. Nieminen *et al* showed that a deletion of the *msh* homeobox 1 gene (*MSX1*), located at 4.9 Mb, might underlie this defect.<sup>34</sup> In contrast to this hypothesis, three patients in this study with deletions in the terminal 2.7 Mb or smaller had oligodontia. Since the carrier of a deletion from 1.1 to 2.5 Mb has oligodontia, the candidate gene has to be sought in this interval. Cleft lip and palate (CL/P) has been observed in nine of 29 patients described in the literature,<sup>9–10</sup> and a candidate region for CL/P was mapped between 150 kb (D4F26) and 2.3 Mb (D4S43).<sup>35</sup> We observed CL/P in a patient with a terminal microdeletion of 3.7 Mb, and in two of eight patients with large deletions. We defined the critical region from 0.3 Mb to 3.7 Mb, but after interpretation of the results of Estabrooks *et al*,<sup>35</sup> this CL/P interval may be refined between 0.3 and 2.3 Mb. Hypospadias was detected in all boys but patient 1 (1.4 Mb deletion). Estabrooks *et al* mapped the critical region for hypospadias between D4S127 (3.0 Mb) and D4S10 (4.0 Mb).<sup>35</sup> Hence our results are concordant with these previous findings. Estabrooks *et al* mapped the critical region for congenital heart defect (CHD) between locus D4S43 and D4S241 proximal from 2.3 Mb.<sup>35</sup> Zollino *et al*<sup>10</sup> and Wieczorek *et al*<sup>9</sup> found CHD in only 13 of 19 patients with large deletions. In the present study, four of eight patients from both large and small deletions presented with a CHD when having a deletion of 3.7 to 14.8 Mb. We refined the region for heart defect proximal from 3.7 Mb.

In conclusion, WHS is a syndrome with a spectrum of phenotypic features, from very subtle and mild to a wide range of severe aberrations. The gene(s) causing the IUGR, postnatal growth retardation and microcephaly are localised in the 0.3 to 1.4 Mb 4pter region. It is conceivable that a single gene might cause all these features. Finally, this study refines the candidate regions for CHD, CL/P, oligodontia and hypospadias. The phenotypic characterisation of more WHS patients will be required to delineate regions involved in these more rare aspects of the WHS phenotype.

**Acknowledgements:** We wish to thank the Micro Array Facility, Flanders Interuniversity Institute for Biotechnology (VIB) for their help in the spotting of the arrays and Children's Hospital Oakland Research Institute (CHORI) for the initial clone supply and verification. This work was made possible by grants OT/02/40, GOA/2006/12 and Centre of Excellence SymBioSys (Research Council K.U.Leuven EF/05/007), Catholic University of Leuven. We wish to thank Mrs R Thoelen for her technical support in FISH analyses and Dr E Chabchoub for his help in screening patients with the 1 Mb array.

**Competing interests:** None declared.

Informed consent was obtained from all patients' legal guardians for publication of the images.

## REFERENCES

- Wolf H, Porsch R, Schroeter R, Baitsch H. Defizienz an den kurzen Arm eines Chromosoms nr. 4. *Humangenetik* 1965;**1**:397–413.
- Hirschhorn K, Cooper HL, Firschein IL. Deletion of short arms of chromosome 4–5 in a child with defects of midline fusion. *Humangenetik* 1965;**1**:479–82.
- Battaglia A, Carey JC, Cederholm P, Viskochil D, Brothman A. Natural history experience with 11 cases of Wolf-Hirschhorn syndrome. *Am J Hum Genet* 1996;**95**:A36.
- Battaglia A, Carey JC. Wolf-Hirschhorn syndrome and Pitt-Rogers-Danks syndrome. *Am J Med Genet* 1998;**75**:541.
- Battaglia A, Carey JC, Cederholm P, Viskochil DH, Brothman AR, Galasso C. Natural history of Wolf-Hirschhorn syndrome: experience with 15 cases. *Pediatrics* 1999;**103**:830–6.
- Battaglia A, Carey JC, Viskochil DH, Cederholm P, Opitz JM. Wolf-Hirschhorn syndrome (WHS): a history in pictures. *Clin Dysmorphol* 2000;**9**:25–30.
- Battaglia A, Carey JC, Wright TJ. Wolf-Hirschhorn (4p-) syndrome. *Adv Pediatr* 2001;**48**:75–113.
- Wright TJ, Clemens M, Quarrell O, Altherr MR. Wolf-Hirschhorn and Pitt-Rogers-Danks syndromes caused by overlapping 4p deletions. *Am J Med Genet* 1998;**75**:345–50.
- Wieczorek D, Krause M, Majewski F, Albrecht B, Horn D, Riess O, Gillesen-Kaesbach G. Effect of the size of the deletion and clinical manifestation in Wolf-Hirschhorn syndrome: analysis of 13 patients with a de novo deletion. *Eur J Hum Genet* 2000;**8**:519–26.
- Zollino M, Di Stefano C, Zampino G, Mastroiacovo P, Wright TJ, Sorge G, Selicorni A, Tenconi R, Zappala A, Battaglia A, Di Rocco M, Palka G, Pallotta R, Altherr MR, Neri G. Genotype-phenotype correlations and clinical diagnostic criteria in Wolf-Hirschhorn syndrome. *Am J Med Genet* 2000;**94**:254–61.
- Zollino M, Lecce R, Fischetto R, Murdolo M, Faravelli F, Selicorni A, Butte C, Memo L, Capovilla G, Neri G. Mapping the Wolf-Hirschhorn syndrome phenotype outside the currently accepted WHS critical region and defining a new critical region, WHSCR-2. *Am J Hum Genet* 2003;**72**:590–7.
- Van Buggenhout G, Melotte C, Dutta B, Froyen G, Van Hummelen P, Marynen P, Matthijs G, de Ravel T, Devriendt K, Fryns JP, Vermeesch JR. Mild Wolf-Hirschhorn syndrome: micro-array CGH analysis of atypical 4p16.3 deletions enables refinement of the genotype-phenotype map. *J Med Genet* 2004;**41**:691–8.
- Zollino M, Lecce R, Selicorni A, Murdolo M, Mancuso I, Marangi G, Zampino G, Garavelli L, Ferrarini A, Rocchi M, Opitz JM, Neri G. A double cryptic chromosome imbalance is an important factor to explain phenotypic variability in Wolf-Hirschhorn syndrome. *Eur J Hum Genet* 2004;**12**:797–804.
- Bergemann AD, Cole F, Hirschhorn K. The etiology of Wolf-Hirschhorn syndrome. *Trends Genet* 2005;**21**:188–95.
- Wright TJ, Ricke DO, Denison K, Abmayr S, Cotter PD, Hirschhorn K, Keinanen M, McDonald-McGinn D, Somer M, Spinner N, Yang-Feng T, Zackai E, Altherr MR. A transcript map of the newly defined 165 kb Wolf-Hirschhorn syndrome critical region. *Hum Mol Genet* 1997;**6**:317–24.
- Rauch A, Schellmoser S, Kraus C, Dorr HG, Trautmann U, Altherr MR, Pfeiffer RA, Reis A. First known microdeletion within the Wolf-Hirschhorn syndrome critical region refines genotype-phenotype correlation. *Am J Med Genet* 2001;**99**:338–42.
- Schlickum S, Moghekar A, Simpson JC, Steglich C, O'Brien RJ, Winterpacht A, Endele SU. LETM1, a gene deleted in Wolf-Hirschhorn syndrome, encodes an evolutionarily conserved mitochondrial protein. *Genomics* 2004;**83**:254–61.
- Fryns JP, de Muelenaere A, Van den Berghe H. The 4p-syndrome in a 24-year-old female. *Ann Genet* 1981;**24**:110–1.
- Fryns JP, Smeets E, Devriendt K, Petit P. Wolf-Hirschhorn syndrome with cryptic 4p16.3 deletion and balanced/unbalanced mosaicism in the mother. *Ann Genet* 1998;**41**:73–6.
- Vermeesch JR, Falzetti D, Van Buggenhout G, Fryns JP, Marynen P. Chromosome healing of constitutional chromosome deletions studied by microdissection. *Cytogenet Cell Genet* 1998;**81**:68–72.
- Manouvrier S, Boute O, Viot G, Delobel B. Deletion of chromosome 4p detected by FISH in a girl with normal high resolution karyotype. *Clin Genet* 1999;**55**:127–9.
- Anderlid BM, Schoumans J, Anneren G, Sahlen S, Kyllerman M, Vujic M, Hagberg B, Blennow E, Nordenskjold M. Subtelomeric rearrangements detected in patients with idiopathic mental retardation. *Am J Med Genet* 2002;**107**:275–84.
- Menten B, Maas N, Thienpont B, Buysse K, Vandesompele J, Melotte C, de Ravel T, Van Vooren S, Balikova I, Backx L, Janssens S, De Paep A, De Moor B, Moreau Y, Marynen P, Fryns JP, Mortier G, Devriendt K, Speleman F, Vermeesch JR. Emerging patterns of cryptic chromosomal imbalance in patients with idiopathic mental retardation and multiple congenital anomalies: a new series of 140 patients and review of published reports. *J Med Genet* 2006;**43**:625–33.
- Maas NMC, Van Vooren S, Hannes F, *et al*. The t(4;8) is mediated by homologous recombination between olfactory receptor gene clusters, but other 4p16 translocations occur at random. *J Genet Counselling* (in press).
- Gentleman RC, Carey VJ, Bates DM, Bolstad B, Dettling M, Dudoit S, Ellis B, Gautier L, Ge Y, Gentry J, Hornik K, Hothorn T, Huber W, Iacus S, Irizarry R, Leisch F, Li C, Maechler M, Rossini AJ, Sawitzki G, Smith C, Smyth G, Tierney L, Yang JY, Zhang J. Bioconductor: open software development for computational biology and bioinformatics. *Genome Biol* 2004;**5**:R80.
- Venkatraman ES, Olshen AB. A faster circular binary segmentation algorithm for the analysis of array CGH data. *Bioinformatics* 2007;**23**:657–63.
- Wright TJ, Costa JL, Naranjo C, Francis-West P, Altherr MR. Comparative analysis of a novel gene from the Wolf-Hirschhorn/Pitt-Rogers-Danks syndrome critical region. *Genomics* 1999;**59**:203–12.
- Marcelis C, Schrander-Stumpel C, Engelen J, Schoonbrood-Lenssen A, Willemse A, Beemer F, Sigaudy S, Missirian C, Philip N, Fryns JP. Wolf-Hirschhorn (4P-) syndrome in adults. *Genet Couns* 2001;**12**:35–48.
- Stec I, Wright TJ, van Ommen GJ, de Boer PA, van Haeringen A, Moorman AF, Altherr MR, den Dunnen JT. WHSC1, a 90 kb SET domain-containing gene, expressed in early development and homologous to a Drosophila dysmorphia gene maps in the Wolf-Hirschhorn syndrome critical region and is fused to IgH in t(4;14) multiple myeloma. *Hum Mol Genet* 1998;**7**:1071–82.

30. **Jongmans MC**, Admiraal RJ, van der Donk KP, Vissers LE, Baas AF, Kapusta L, van Hagen JM, Donnai D, de Ravel TJ, Veltman JA, Geurts van Kessel A, De Vries BB, Brunner HG, Hoefsloot LH, van Ravenswaaij CM. CHARGE syndrome: the phenotypic spectrum of mutations in the CHD7 gene. *J Med Genet* 2006;**43**:306–14.
31. **Tonkin ET**, Wang TJ, Lisgo S, Bamshad MJ, Strachan T. NIPBL, encoding a homolog of fungal Scc2-type sister chromatid cohesion proteins and fly Nipped-B, is mutated in Cornelia de Lange syndrome. *Nat Genet* 2004;**36**:636–41.
32. **Aoki Y**, Niihori T, Kawame H, Kurosawa K, Ohashi H, Tanaka Y, Filocamo M, Kato K, Suzuki Y, Kure S, Matsubara Y. Germline mutations in HRAS proto-oncogene cause Costello syndrome. *Nat Genet* 2005;**37**:1038–40.
33. **Endele S**, Fuhry M, Pak SJ, Zabel BU, Winterpacht A. LETM1, a novel gene encoding a putative EF-hand Ca(2+)-binding protein, flanks the Wolf-Hirschhorn syndrome (WHS) critical region and is deleted in most WHS patients. *Genomics* 1999;**60**:218–25.
34. **Nieminen P**, Kotilainen J, Aalto Y, Knuutila S, Pirinen S, Thesleff I. MSX1 gene is deleted in Wolf-Hirschhorn syndrome patients with oligodontia. *J Dent Res* 2003;**82**:1013–7.
35. **Estabrooks LL**, Rao KW, Driscoll DA, Crandall BF, Dean JC, Ikonen E, Korf B, Aylsworth AS. Preliminary phenotypic map of chromosome 4p16 based on 4p deletions. *Am J Med Genet* 1995;**57**:581–6.

### BMJ Clinical Evidence—Call for contributors

*BMJ Clinical Evidence* is a continuously updated evidence-based journal available worldwide on the internet which publishes commissioned systematic reviews. *BMJ Clinical Evidence* needs to recruit new contributors. Contributors are healthcare professionals or epidemiologists with experience in evidence-based medicine, with the ability to write in a concise and structured way and relevant clinical expertise.

#### Areas for which we are currently seeking contributors:

- ▶ Secondary prevention of ischaemic cardiac events
- ▶ Acute myocardial infarction
- ▶ MRSA (treatment)
- ▶ Bacterial conjunctivitis

However, we are always looking for contributors, so do not let this list discourage you.

#### Being a contributor involves:

- ▶ Selecting from a validated, screened search (performed by in-house Information Specialists) valid studies for inclusion.
- ▶ Documenting your decisions about which studies to include on an inclusion and exclusion form, which we will publish.
- ▶ Writing the text to a highly structured template (about 1500–3000 words), using evidence from the final studies chosen, within 8–10 weeks of receiving the literature search.
- ▶ Working with *BMJ Clinical Evidence* editors to ensure that the final text meets quality and style standards.
- ▶ Updating the text every 12 months using any new, sound evidence that becomes available. The *BMJ Clinical Evidence* in-house team will conduct the searches for contributors; your task is to filter out high quality studies and incorporate them into the existing text.
- ▶ To expand the review to include a new question about once every 12 months.

In return, contributors will see their work published in a highly-rewarded peer-reviewed international medical journal. They also receive a small honorarium for their efforts.

If you would like to become a contributor for *BMJ Clinical Evidence* or require more information about what this involves please send your contact details and a copy of your CV, clearly stating the clinical area you are interested in, to [CECommissioning@bmjgroup.com](mailto:CECommissioning@bmjgroup.com).

#### Call for peer reviewers

*BMJ Clinical Evidence* also needs to recruit new peer reviewers specifically with an interest in the clinical areas stated above, and also others related to general practice. Peer reviewers are healthcare professionals or epidemiologists with experience in evidence-based medicine. As a peer reviewer you would be asked for your views on the clinical relevance, validity and accessibility of specific reviews within the journal, and their usefulness to the intended audience (international generalists and healthcare professionals, possibly with limited statistical knowledge).

Reviews are usually 1500–3000 words in length and we would ask you to review between 2–5 systematic reviews per year. The peer review process takes place throughout the year, and our turnaround time for each review is 10–14 days. In return peer reviewers receive free access to *BMJ Clinical Evidence* for 3 months for each review.

If you are interested in becoming a peer reviewer for *BMJ Clinical Evidence*, please complete the peer review questionnaire at [www.clinicalevidence.com/ceweb/contribute/peerreviewer.jsp](http://www.clinicalevidence.com/ceweb/contribute/peerreviewer.jsp)