





OPEN ACCESS

Original research

Craniofacial features of POLR3-related leukodystrophy caused by biallelic variants in *POLR3A*, *POLR3B* and *POLR1C*

Amytice Mirchi ^{1,2,3} Simon-Pierre Guay,^{4,5} Luan T Tran,^{1,3} Nicole I Wolf,⁶ Adeline Vanderver,^{7,8} Bernard Brais,^{1,4,9} Michel Sylvain,¹⁰ Daniela Pohl,¹¹ Elsa Rossignol,¹² Michael Saito,¹³ Sebastien Moutton,¹⁴ Luis González-Gutiérrez-Solana,¹⁵ Isabelle Thiffault,^{16,17} Michael C Kruer ^{18,19,20} Dolores Gonzales Moron,²¹ Marcelo Kauffman,²² Cyril Goizet,^{23,24} László Sztriha,²⁵ Emma Glamuzina,²⁶ Serge B Melançon,²⁷ Sakkubai Naidu,²⁸ Jean-Marc Retrouvey,²⁹ Suzanne Lacombe,²⁹ Beatriz Bernardino-Cuesta,³⁰ Isabelle De Bie,^{4,5,31} Geneviève Bernard^{1,2,3,4,5}

► Additional supplemental material is published online only. To view, please visit the journal online (<http://dx.doi.org/10.1136/jmg-2023-109223>).

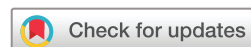For numbered affiliations see end of article.

Correspondence to

Dr Geneviève Bernard, Departments of Neurology and Neurosurgery, Pediatrics, and Human Genetics, McGill University & Department of Specialized Medicine, Division of Medical Genetics, McGill University Health Centre, Montreal, Canada; genevieve.bernard@mcgill.ca

AM and S-PG contributed equally.
IDB and GB contributed equally.

Received 16 February 2023
Accepted 16 April 2023
Published Online First 16 May 2023



© Author(s) (or their employer(s)) 2023. Re-use permitted under CC BY. Published by BMJ.

To cite: Mirchi A, Guay S-P, Tran LT, et al. *J Med Genet* 2023;**60**:1026–1034.

ABSTRACT

Background RNA polymerase III-related or 4H leukodystrophy (POLR3-HLD) is an autosomal recessive hypomyelinating leukodystrophy characterized by neurological dysfunction, hypodontia and hypogonadotropic hypogonadism. The disease is caused by biallelic pathogenic variants in *POLR3A*, *POLR3B*, *POLR1C* or *POLR3K*. Craniofacial abnormalities reminiscent of Treacher Collins syndrome have been originally described in patients with POLR3-HLD caused by biallelic pathogenic variants in *POLR1C*. To date, no published studies have appraised in detail the craniofacial features of patients with POLR3-HLD. In this work, the specific craniofacial characteristics of patients with POLR3-HLD associated with biallelic pathogenic variants in *POLR3A*, *POLR3B* and *POLR1C* are described.

Methods The craniofacial features of 31 patients with POLR3-HLD were evaluated, and potential genotype–phenotype associations were evaluated.

Results Various craniofacial abnormalities were recognized in this patient cohort, with each individual presenting at least one craniofacial abnormality. The most frequently identified features included a flat midface (61.3%), a smooth philtrum (58.0%) and a pointed chin (51.6%). In patients with *POLR3B* biallelic variants, a thin upper lip was frequent. Craniofacial anomalies involving the forehead were most commonly associated with biallelic variants in *POLR3A* and *POLR3B* while a higher proportion of patients with *POLR1C* biallelic variants demonstrated bitemporal narrowing.

Conclusion Through this study, we demonstrated that craniofacial abnormalities are common in patients with POLR3-HLD. This report describes in detail the dysmorphic features of POLR3-HLD associated with biallelic variants in *POLR3A*, *POLR3B* and *POLR1C*.

INTRODUCTION

Leukodystrophies are a group of rare heterogenous inherited disorders that affect the cerebral white matter and are typically associated with progressive

WHAT IS ALREADY KNOWN ON THIS TOPIC

⇒ Craniofacial abnormalities in patients harbouring biallelic pathogenic variants in genes encoding different subunits of RNA polymerases including RNA polymerase III have been described only for a specific small subset of phenotypes, that is, Treacher Collins syndrome/POLR1C-related HLD and Wiedemann-Rautenstrauch syndrome. Despite this, description of craniofacial features in individuals with RNA polymerase III-related hypomyelinating leukodystrophy (POLR3-HLD) is currently very limited.

WHAT THIS STUDY ADDS

⇒ This is the first study to explore and assess the craniofacial features of a cohort of patients with POLR3-HLD. It is the only study proposing genotype–phenotype correlations based on facial features identified in patients with POLR3-HLD.

HOW THIS STUDY MIGHT AFFECT RESEARCH, PRACTICE OR POLICY

⇒ This study is the first to describe the specific phenotypic spectrum of craniofacial anomalies in POLR3-HLD. This detailed account will assist clinicians in diagnosing this condition and will therefore help to provide care directed to this patient population's specific needs. It will also allow future studies characterizing the underlying pathophysiology of this condition. Indeed, the pathophysiological relationship between biallelic pathogenic variants in a housekeeping gene and specific organ involvement remains to this day unresolved. Characterizing the entire clinical spectrum of this condition will help guide future studies in understanding disease pathogenicity, opening the door for therapy development.

neurodegeneration.¹ Although individually rare, they collectively affect 1 in 4733 live births.² The clinical manifestations of this group of disorders can appear at any time from infancy to adulthood and may include developmental delay and/or regression, cerebellar features, gait difficulties, pyramidal and extrapyramidal signs, seizures, cognitive and psychiatric manifestations.³

RNA polymerase III-related hypomyelinating leukodystrophy (POLR3-HLD; MIM: 607694, 614381, 616494), one of the most common hypomyelinating leukodystrophies, is an autosomal recessive disorder caused by biallelic pathogenic variants in *POLR3A*, *POLR3B*, *POLR1C* or *POLR3K*, each encoding subunits of RNA polymerase III.^{4–10} *POLR3A* and *POLR3B* encode the largest subunits that form the catalytic core of RNA polymerase III. *POLR1C* encodes a subunit of both RNA polymerase I and III while *POLR3K* encodes for a different subunit of RNA polymerase III.^{4–7 11} RNA polymerase III is a crucial enzyme responsible for the transcription of small RNAs including transfer RNAs, 5S ribosomal RNA and U6 small nuclear RNA. These are implicated in transcriptional activity regulation, RNA processing, ribosomal assembly and translation necessary for protein synthesis.^{12 13}

POLR3-HLD is also known as 4H leukodystrophy in reference to the phenotypic constellation of hypomyelination in addition to hypodontia and hypogonadotropic hypogonadism.^{14–17} Onset of symptoms is typically in early childhood with evidence of motor dysfunction including predominant cerebellar signs in addition to cognitive impairment, abnormal dentition including hypodontia, oligodontia or delayed dentition, endocrinological abnormalities including short stature, delayed or absent puberty and ocular abnormalities, particularly progressive myopia. In addition to the classical hypomyelinating leukodystrophy pattern consisting of mild T2 hyperintensity and variable T1 signal of the white matter compared with grey matter structures, brain MRI typically reveals relative preservation of myelination (i.e., hypointense T2 signal) of specific structures including the dentate nuclei, anterolateral nuclei of the thalami, globi pallidi, pyramidal tracts in the posterior limbs of the internal capsules and optic radiations. In addition, cerebellar atrophy and thinning of the corpus callosum are commonly present.^{14 15 18 19}

In recent years, the phenotypic spectrum of POLR3-related disorders has enlarged significantly, including severe neonatal and infantile presentations to late onset mild ones.^{20–32} Reports of craniofacial characteristics of individuals with POLR3-related disorders are scarce and include patients with biallelic pathogenic variants in *POLR1C*,¹⁴ a gene also associated with Treacher Collins syndrome (TCS), as well as patients with Wiedemann-Rautenstrauch syndrome (WRS) associated with biallelic pathogenic variants in *POLR3A*.²¹ However, to this day, there have been no studies specifically dedicated to exploring the craniofacial features in POLR3-HLD. Here, we further expand the phenotypic description of POLR3-HLD caused by biallelic variants in *POLR3A*, *POLR3B* and *POLR1C* by systematically assessing and characterizing the craniofacial features of 31 identified affected individuals.

METHODS

Thirty-one individuals were included in this single-centre cross-sectional study. The participants were included based on the clinical and radiological features in keeping with a POLR3-HLD diagnosis in addition to biallelic pathogenic or likely pathogenic variants in *POLR3A*, *POLR3B* or *POLR1C* identified by gene panels, exome or genome sequencing using DNA extracted from whole blood according to standard protocols. Interpretation of

sequence variants were done as per consensus recommendation of the American College of Medical Genetics and Genomics and the Association for Molecular Pathology.³¹ Only pathogenic and likely pathogenic variants were considered as disease causing. Variants were described based on reference sequence GRCh37 (NM_007055.4 for *POLR3A*, NM_018082.6 for *POLR3B* and NM_203290.4 for *POLR1C*). Compliance with HGVS nomenclature has been verified using VariantValidator. In addition, participants were selected based on availability of photographs of adequate quality for craniofacial analysis. The individuals were recruited at the Montreal Children's Hospital of the McGill University Health Center between 2012 and 2021.

Facial images including face front and/or profile views of each individual with POLR3-HLD were independently reviewed by two specialists in dysmorphology (SPG and IDB). Both observers were blinded to the genotype. The two physicians performing the dysmorphologic evaluations of patients reviewed and scored all provided pictures independently using 'Elements of morphology: standard terminology for the head and face' as a reference.³³ All evaluations were subsequently revised jointly. There were no instances of significant discordance in scoring and description. Occasional omissions of scoring of some features was the only noted difference. This was resolved through the joint revision of features initially omitted.

Pearson χ^2 was used to investigate the association between the presence of craniofacial features and the genotype, that is, *POLR3A*, *POLR3B* or *POLR1C* biallelic variants. Only features present in at least 10% of the patients (>3/31) were included for comparison. Identified craniofacial features were also grouped based on their location (forehead, eyes, philtrum, lip and chin). The individual carrying variants in *POLR3A* and *POLR3B* (subject 31) was excluded from the statistical analysis. Results were considered statistically significant when p values were less than 0.05 (two-sided). All statistical analyses were performed with the IBM SPSS Statistics 28 software (release 28.0.0).

RESULTS

Among the 31 participants, there were 21 males (67.7%) and 10 females (32.3%). All thirty-one participants had a confirmed diagnosis of POLR3-HLD on the basis of their clinical and radiological features in addition to molecularly confirmed presence of likely pathogenic or pathogenic variants in *POLR3A*, *POLR3B* or *POLR1C* (table 1). Variants were present either in the compound heterozygous or homozygous state in each patient. Sixteen participants had biallelic variants in *POLR3A* (51.6%), ten in *POLR3B* (32.2%) and four in *POLR1C* (12.9%). One participant (subject 31) had a combination of a pathogenic and likely pathogenic variant in *POLR3A* in addition to a pathogenic and a deep intronic variant of unknown significance in *POLR3B*. In this participant, we believe that the *POLR3A* variants are disease causing, either solely or in combination with the *POLR3B* variants.

All individuals presented at least one craniofacial abnormality (figure 1 and online supplemental file 1). Although some of these could be familial, a subset of craniofacial abnormalities was described in more than 50% of the individuals. In total, 16 craniofacial abnormalities were recognized in at least 10% of the individuals, including a high anterior hairline, high forehead, bitemporal narrowing, hypertelorism, telecanthus, long palpebral fissures, low-set ears, flat midface, pinched nose, bulbous tip of the nose, short and/or smooth philtrum, thin upper lip, full lower lip, short chin and pointed chin. Our analysis revealed that more than half of the subjects in our cohort have craniofacial

Table 1. Description of the pathogenic or likely pathogenic variants identified in our subjects

Subject	Sex	Gene	cDNA variant	Protein	Zygosity	Previous publication(s)
POLR3A						
Subject 1	Male	POLR3A POLR3A	c.1674C>G c.3742_3743insACC	p.F558L p.1248insT	cHET	Bernard <i>et al</i> (2010) <i>Neurogenetics</i> ⁴³ ; Bernard <i>et al</i> (2011) <i>Am J Hum Genet</i> ⁴ ; Wolf <i>et al</i> (2014) <i>Neuro</i> ¹⁵ ; Al Yazidi <i>et al</i> (2019) <i>Mov Disord Clin Pract</i> ⁴⁴ ; Pelletier <i>et al</i> (2020) <i>J Clin Endocr</i> ⁴⁵
Subject 2	Male	POLR3A	c.2015G>A	p.G672E	HMZ	Bernard <i>et al</i> (2010) <i>Neurogenetics</i> ⁴³ ; Bernard <i>et al</i> (2011) <i>Am J Hum Genet</i> ⁴ ; Wolf <i>et al</i> (2014) <i>Neuro</i> ¹⁵ ; Al Yazidi <i>et al</i> (2019) <i>Mov Disord Clin Pract</i> ⁴⁴ ; Pelletier <i>et al</i> (2020) <i>J Clin Endocr</i> ⁴⁵
Subject 3	Male	POLR3A	c.2015G>A	p.G672E	HMZ	Bernard <i>et al</i> (2010) <i>Neurogenetics</i> ⁴³ ; Bernard <i>et al</i> (2011) <i>Am J Hum Genet</i> ⁴ ; Wolf <i>et al</i> (2014) <i>Neuro</i> ¹⁵ ; Mirchi <i>et al</i> (2018) <i>Pediatr Neurol</i> ⁴⁶ ; Al Yazidi <i>et al</i> (2019) <i>Mov Disord Clin Pract</i> ⁴⁴ ; Pelletier <i>et al</i> (2020) <i>J Clin Endocr</i> ⁴⁵
Subject 4	Female	POLR3A	c.2015G>A	p.G672E	HMZ	Bernard <i>et al</i> (2011) <i>Am J Hum Genet</i> ⁴ ; Wolf <i>et al</i> (2014) <i>Neuro</i> ¹⁴ ; Pelletier <i>et al</i> (2020) <i>J Clin Endocr</i> ⁴⁵
Subject 5	Male	POLR3A POLR3A	c.2015G>A c.3718G>A	p.G672E p.G1240S	cHET	Wolf <i>et al</i> (2014) <i>Neuro</i> ¹⁴ ; Mirchi <i>et al</i> (2018) <i>Pediatr Neurol</i> ⁴⁶ ; Al Yazidi <i>et al</i> (2019) <i>Mov Disord Clin Pract</i> ⁴⁴ ; Pelletier <i>et al</i> (2020) <i>J Clin Endocr</i> ⁴⁵
Subject 6	Male	POLR3A POLR3A	c.1674C>G c.2015G>A	p.F558L p.G672E	cHET	Wolf <i>et al</i> (2014) <i>Neuro</i> ¹⁵ ; Mirchi <i>et al</i> (2018) <i>Pediatr Neurol</i> ⁴⁶ ; Al Yazidi <i>et al</i> (2019) <i>Mov Disord Clin Pract</i> ⁴⁴ ; Pelletier <i>et al</i> (2020) <i>J Clin Endocr</i> ⁴⁵
Subject 7	Male	POLR3A POLR3A	c.3583del c.1771-7C>G	p.D1195Ifs*47 p.E548_Y637del/p.P591Mfs*9	cHET	Perrier <i>et al</i> (2020) <i>Neurol-Genet</i> ²⁰
Subject 8	Male	POLR3A POLR3A	c.1771-6C>G c.3205C>T	p.P591Mfs*9 p.R1069W	cHET	La Piana <i>et al</i> (2016) <i>Neuro</i> ²⁵ ; Pelletier <i>et al</i> (2020) <i>J Clin Endocr</i> ⁴⁵
Subject 9	Female	POLR3A POLR3A	c.3014G>A c.3781G>A	p.R1005H p.E1261K	cHET	Wolf <i>et al</i> (2014) <i>Neuro</i> ¹⁵ ; Mirchi <i>et al</i> (2018) <i>Pediatr Neurol</i> ⁴⁶ ; Cordoba <i>et al</i> (2018) <i>PLoS One</i> ⁴⁷ ; Al Yazidi <i>et al</i> (2019) <i>Mov Disord Clin Pract</i> ⁴⁴ ; Pelletier <i>et al</i> (2020) <i>J Clin Endocr</i> ⁴⁵
Subject 10	Male	POLR3A POLR3A	c.1771-6C>G c.2819_2820del	p.P591Mfs*9 p.L940Qfs*17	cHET	N/A
Subject 11	Male	POLR3A POLR3A	c.1771-7C>G c.3387C>A	p.E548_Y637del/p.P591Mfs*9 p.L1129=	cHET	Harting <i>et al</i> (2020) <i>Neurogenetics</i> ²⁷
Subject 12	Female	POLR3A POLR3A	c.1369G>A c.3242+2A>G	p.G457R —	cHET	Mirchi <i>et al</i> (2018) <i>Pediatr Neurol</i> ⁴⁶ ; Al Yazidi <i>et al</i> (2019) <i>Mov Disord Clin Pract</i> ⁴⁴ ; Pelletier <i>et al</i> (2020) <i>J Clin Endocr</i> ⁴⁵
Subject 13	Female	POLR3A POLR3A	c.2554A>G c.2617-1G>A	p.M852V p.R873Afs*878	cHET	Timmons <i>et al</i> (2006) <i>Neuro</i> ¹⁶ ; Bernard <i>et al</i> (2011) <i>Am J Hum Genet</i> ⁴ ; Wolf <i>et al</i> (2014) <i>Neuro</i> ¹⁵ ; Al Yazidi <i>et al</i> (2019) <i>Mov Disord Clin Pract</i> ⁴⁴ ; Pelletier <i>et al</i> (2020) <i>J Clin Endocr</i> ⁴⁵
Subject 14	Male	POLR3A POLR3A	c.1186G>T c.2015G>A	p.V396L p.G672E	cHET	Wolf <i>et al</i> (2014) <i>Neuro</i> ¹⁵ ; Mirchi <i>et al</i> (2018) <i>Pediatr Neurol</i> ⁴⁶ ; Al Yazidi <i>et al</i> (2019) <i>Mov Disord Clin Pract</i> ⁴⁴ ; Pelletier <i>et al</i> (2020) <i>J Clin Endocr</i> ⁴⁵
Subject 15	Male	POLR3A	c.1909+18G>A	p.Y637Cfs*14	HMZ	Al Yazidi <i>et al</i> (2019) <i>Mov Disord Clin Pract</i> ⁴⁴ ; Pelletier <i>et al</i> (2020) <i>J Clin Endocr</i> ⁴⁵
Subject 16	Male	POLR3A POLR3A	c.1051C>T c.1771-7C>G	p.R351* p.E548_Y637del/p.P591Mfs*9	cHET	Perrier <i>et al</i> (2020) <i>Neurol-Genet</i> ²⁰
POLR3B						
Subject 17	Female	POLR3B	c.1324C>T c.1568T>A	p.R442C p.V523E	cHET	Wolf <i>et al</i> (2014) <i>Neuro</i> ¹⁵ ; Daoud <i>et al</i> (2013) <i>J Med Genet</i> ⁹ ; Al Yazidi <i>et al</i> (2019) <i>Mov Disord Clin Pract</i> ⁴⁴ ; Pelletier <i>et al</i> (2020) <i>J Clin Endocr</i> ⁴⁵
Subject 18	Female	POLR3B	c.1568T>A	p.V523E	HMZ	Wolf <i>et al</i> (2014) <i>Neuro</i> ¹⁵ ; Al Yazidi <i>et al</i> (2019) <i>Mov Disord Clin Pract</i> ⁴⁴ ; Perrier <i>et al</i> (2020) <i>Neurol-Genet</i> ²⁰ ; DeGasperi <i>et al</i> (2020) <i>Neurol-Genet</i> ⁴⁸ ; Pelletier <i>et al</i> (2020) <i>J Clin Endocr</i> ⁴⁵
Subject 19	Male	POLR3B	c.1568T>A	p.V523E	HMZ	Wolf <i>et al</i> (2014) <i>Neuro</i> ¹⁵ ; Perrier <i>et al</i> (2020) <i>Neurol-Genet</i> ²⁰ ; DeGasperi <i>et al</i> (2020) <i>Neurol-Genet</i> ⁴⁸ ; Pelletier <i>et al</i> (2020) <i>J Clin Endocr</i> ⁴⁵
Subject 20	Male	POLR3B	c.312G>T c.2570+1G>A	p.L104F p.G818fs	cHET	Wolf <i>et al</i> (2014) <i>Neuro</i> ¹⁵ ; Mirchi <i>et al</i> (2018) <i>Pediatr Neurol</i> ⁴⁶
Subject 21	Male	POLR3B	c.1568T>A c.1947_1951del	p.V523E p.N650Lfs*46	cHET	Mirchi <i>et al</i> (2018) <i>Pediatr Neurol</i> ⁴⁶ ; Pelletier <i>et al</i> (2020) <i>J Clin Endocr</i> ⁴⁵
Subject 22	Male	POLR3B	c.496+3A>G	—	HMZ	N/A
Subject 23	Female	POLR3B	c.1568T>A c.2740G>A	p.V523E p.E914K	cHET	N/A
Subject 24	Male	POLR3B	c.1999G>A c.2084-6A>G	p.V667M p.G695Vfs*5	cHET	N/A
Subject 25	Male	POLR3B	c.1999G>A c.2084-6A>G	p.V667M p.G695Vfs*5	cHET	N/A

Continued

Table 1. Continued

Subject	Sex	Gene	cDNA variant	Protein	Zygosity	Previous publication(s)
Subject 26	Female	<i>POLR3B</i>	c.1568T>A c.2818–2A>T	p.V523E –	cHET	Mirchi <i>et al</i> (2018) <i>Pediatr Neurol</i> ⁴⁶
<i>POLR1C</i>						
Subject 27	Male	<i>POLR1C</i>	c.88C>T c.615del	p.P30S p.Q206Kfs*48	cHET	Gauquelin <i>et al</i> (2019) <i>Neurol-Genet</i> ¹⁴
Subject 28	Female	<i>POLR1C</i>	c.699C>G c.883_885del	p.Y233* p.K295del	cHET	Gauquelin <i>et al</i> (2019) <i>Neurol-Genet</i> ¹⁴
Subject 29	Female	<i>POLR1C</i>	c.77C>T c.326G>A	p.T26I p.R109H	cHET	Thiffault <i>et al</i> (2015) <i>Nat Commun</i> ⁶ ; Gauquelin <i>et al</i> (2019) <i>Neurol-Genet</i> ¹⁴
Subject 30	Male	<i>POLR1C</i>	c.221A>G	p.N74S	HMZ	Thiffault <i>et al</i> (2015) <i>Nat Commun</i> ⁶ ; Gauquelin <i>et al</i> (2019) <i>Neurol-Genet</i> ¹⁴
<i>POLR3A</i> (±<i>POLR3B</i>)						
Subject 31 *	Male	<i>POLR3A</i>	c.2434G>A deletion of exon 6-8	p.G812S –	cHET	Mirchi <i>et al</i> (2018) <i>Pediatr Neurol</i> ⁴⁶ ; Pelletier <i>et al</i> (2020) <i>J Clin Endocr</i> ⁴⁵
		<i>POLR3A</i>	c.1006G>A	p.A336T		
		<i>POLR3B</i>	c.72+294C>A†	–		
		<i>POLR3B</i>			cHET	
DNA sequence variants were described based on referring sequence NM_007055.4 for <i>POLR3A</i> , NM_018082.6 for <i>POLR3B</i> and NM_203290.4 for <i>POLR1C</i> (GRCh37).						
*In this patient, the biallelic <i>POLR3A</i> variants are disease causing, either solely or in combination with the <i>POLR3B</i> variants						
†This variant is of unknown significance						
cHET, compound heterozygous; HMZ, homozygous.						

abnormalities involving the eyes, the midface, the philtrum or the chin. A flat midface (61.3%; 19/31), smooth philtrum (58.0%; 18/31) and pointed chin (51.6%; 16/31) were the most common craniofacial features observed (figure 2). Moreover, 83.9% (26/31) of subjects had an anomaly of the philtrum with either a short and/or smooth philtrum. Seventy-one per cent (22/31) of patients had an anomaly of the chin consisting of a short and/or pointed chin. An anomaly of the eyes was seen in 51.6% (16/31) of subjects with hypertelorism, telecanthus and/or long palpebral fissures. Interestingly, subject 28, previously published,¹⁴ who has biallelic variants in *POLR1C*, whose photograph is shown in figure 1, displayed some craniofacial features typically observed

in TCS including bitemporal narrowing, downsloping palpebral fissures and abnormalities of the external ears. As shown in table 2, comparisons of the craniofacial abnormalities based on underlying genotype revealed some distinctive features between the three groups of patients. More specifically, a statistically significant difference was identified between genotypes and the presence of a thin upper lip. Patients with biallelic variants in *POLR3B* were found to most frequently display a thin upper lip as opposed to patients with *POLR3A* and *POLR1C* biallelic variants (p=0.036). *POLR3B* patients were identified more frequently as presenting a thin upper lip compared with *POLR3A* patients (p=0.011). Craniofacial abnormalities




Figure 1 Craniofacial characteristics in patients with *POLR3*-HLD by genotype. Selection of representative pictures of our patient cohort are shown. Anomaly of the lower face including a flat midface (subjects 5, 7, 9, 12, 20, 23, 27, 31), smooth philtrum (subjects 1, 9, 12, 21, 26, 27, 31) and pointed chin (subjects 1, 5, 11, 12, 21, 26, 27, 31) were among the most common craniofacial features in our cohort of patients. ¹This patient also has a variant of unknown significance and a pathogenic variant in *POLR3B*.

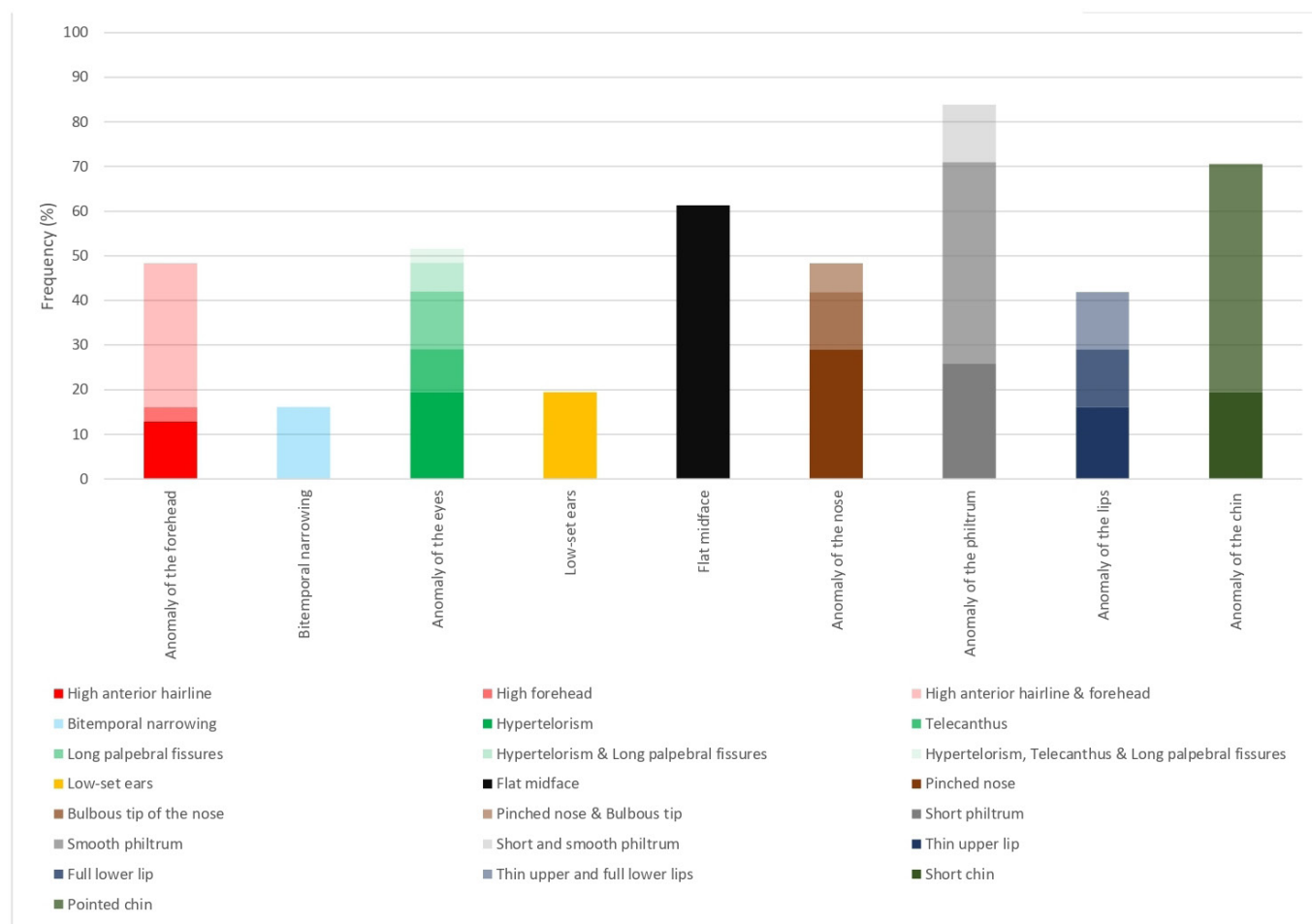


Figure 2 Frequency of the craniofacial features described in our cohort of patients with POLR3-HLD.

involving the forehead characterized as a high anterior hairline and/or a high forehead were found to be most common in individuals with *POLR3A* (50.0%; 8/16) and *POLR3B* (60%; 6/10) pathogenic variants as opposed to *POLR1C*, with none of our four *POLR1C* patients being described as having an anomaly of the forehead. There was a statistically significant difference between the *POLR3B* and *POLR1C* groups with a *p* value of 0.040 when evaluating for the presence of an anomaly of the forehead. On the other hand, bitemporal narrowing was identified most commonly in patients with *POLR1C* variants (50.0%; 2/4) as opposed to patients with *POLR3A* variants (18.8%; 3/16). Bitemporal narrowing was absent in all our patients with *POLR3B* variants. When comparing the groups of patients with *POLR3B* and *POLR1C* variants, there was a statistically significant difference supporting that the presence of bitemporal narrowing is most commonly seen in *POLR1C* patients (*p*=0.016).

DISCUSSION

Our study illustrates the various craniofacial features present in patients with POLR3-HLD caused by biallelic variants in *POLR3A*, *POLR3B* and *POLR1C*. Anomalies of the lower face including a flat midface, smooth philtrum and pointed chin were among the most common craniofacial features in our cohort of patients. In addition, genotype–phenotype correlations enabled the identification of differences between the craniofacial features and underlying genotype of patients. Presence of a thin upper lip was most frequently associated with *POLR3B* biallelic variants

while patients with *POLR3A* variants were most commonly found to have forehead abnormalities. In addition, bitemporal narrowing was associated with underlying *POLR1C* biallelic variants. The gene-specific dysmorphic features described in this study are additional clues that could help clinicians suspect POLR3-HLD in patients presenting with a hypomyelinating leukodystrophy.

Specific craniofacial characteristics have previously been associated with biallelic variants in various genes encoding four RNA polymerase III subunits. WRS is a neonatal progeroid disorder characterized by premature ageing and associated with intra-uterine growth restriction, postnatal growth failure, short stature, lipodystrophy, hypotonia and intellectual disability.^{21 23 34} A previous study in 2018 identified specific combinations of biallelic *POLR3A* variants associated with WRS. It was hypothesized that the specific combinations of compound heterozygous variants in this gene correlate with the WRS disease phenotype.^{14 20} Individuals with WRS typically have a characteristic facial appearance with a triangular facies, sparse scalp hair, an enlarged fontanelle, prominent scalp veins, a pointed chin, a convex or pinched nose, low-set eyes, a small mouth and dental abnormalities reminiscent of what can be seen in patients with POLR3-HLD including presence of natal teeth or hypodontia.^{21 23 34} In 2021, report of pathogenic compound heterozygous variants in *POLR3B* in a patient with WRS led to further expansion of the genotypic spectrum of this condition.²³ A prior study has also identified a nonsense variant in *POLR3GL*, a gene encoding another subunit of RNA polymerase III, as being associated with WRS.²²

Table 2 Craniofacial features of POLR3-HLD patients according to genotype

Craniofacial features	<i>POLR3A</i> (n=16)	<i>POLR3B</i> (n=10)	<i>POLR1C</i> (n=4)	p-value	p-value (3A vs 3B)	p-value (3A vs 1C)	p-value (3B vs 1C)
High anterior hairline	8 (50.0)	5 (50.0)	0	0.171	1	0.068	0.078
High forehead	6 (37.5)	4 (40.0)	0	0.313	0.899	0.143	0.134
Anomaly of the forehead*	8 (50.0)	6 (60.0)	0	0.117	0.619	0.068	0.040
Bitemporal narrowing	3 (18.8)	0	2 (50.0)	0.072	0.145	0.197	0.016
Hypertelorism	6 (37.5)	2 (20.0)	1 (25.0)	0.621	0.347	0.639	0.837
Telecanthus	1 (6.3)	2 (20.0)	1 (25.0)	0.461	0.286	0.264	0.837
Long palpebral fissures	3 (18.8)	4 (40.0)	0	0.228	0.235	0.348	0.134
Anomaly of the eyes†	7 (43.8)	7 (70.0)	2 (50.0)	0.422	0.191	0.822	0.480
Low-set ears	2 (12.5)	2 (20.0)	1 (25.0)	0.787	0.606	0.531	0.837
Flat midface	10 (62.5)	6 (60.0)	2 (50.0)	0.901	0.899	0.648	0.733
Pinched nose	6 (37.5)	4 (40.0)	1 (25.0)	0.866	0.899	0.639	0.597
Bulbous tip of the nose	3 (18.8)	1 (10.0)	1 (25.0)	0.752	0.547	0.780	0.469
Anomaly of the nose‡	8 (50.0)	4 (40.0)	2 (50.0)	0.875	0.619	1	0.733
Short philtrum	7 (43.8)	3 (30.0)	2 (50.0)	0.713	0.483	0.822	0.480
Smooth philtrum	7 (43.8)	8 (80.0)	2 (50.0)	0.185	0.069	0.822	0.262
Anomaly of the philtrum§	13 (81.3)	8 (80.0)	4 (100)	0.628	0.937	0.348	0.334
Thin upper lip	2 (12.5)	6 (60.0)	1 (25.0)	0.036	0.011	0.531	0.237
Full lower lip	3 (18.8)	4 (40.0)	1 (25.0)	0.490	0.235	0.780	0.597
Anomaly of the lips¶	4 (25.0)	7 (70.0)	2 (50.0)	0.076	0.024	0.329	0.480
Short chin	3 (18.8)	3 (30.0)	0	0.440	0.508	0.348	0.217
Pointed chin	9 (56.3)	3 (30.0)	3 (75.0)	0.241	0.191	0.494	0.124
Anomaly of the chin**	12 (75.0)	6 (60.0)	3 (75.0)	0.700	0.420	1	0.597

Pearson χ^2 was used to investigate the association between the presence of craniofacial features and the genotype.

P-values are reported for the 3-group comparison (1st column) as well as 2-group comparisons (2nd, 3rd and 4th columns). A p-value below 0.05 suggest a statistical difference for the craniofacial feature prevalence between the groups and are shown in bold. P-values below 0.10 are shown in italic. Only features present in at least 10% of the sample (>3/31) were included for comparison. The individual carrying pathogenic variants in *POLR3A* and 1 pathogenic variant and 1 variant of unknown significance in *POLR3B* (subject 31) was excluded from the statistical analysis (n=30). Identified craniofacial features were also grouped based on their location.

*Anomaly of the forehead included a high anterior hairline or a high forehead.

†Anomaly of the eyes included hypertelorism, telecanthus or long palpebral fissures.

‡Anomaly of the nose included a pinched nose or a bulbous tip of the nose.

§Anomaly of the philtrum included a short or smooth philtrum.

¶Anomaly of the lips included a thin upper or a full lower lip.

**Anomaly of the chin included a short or pointed chin.

TCS is a disorder presenting with specific craniofacial features caused by defects of embryogenesis of the first and second brachial arches, most often transmitted as an autosomal dominant condition. TCS is characterized by downslanting palpebral fissures, facial bone hypoplasia, micrognathia and external ear anomalies including microtia in addition to conductive hearing loss.^{35–37} Some individuals with TCS may also have a cleft palate or choanal atresia.³⁷ Although TCS is most frequently attributed to heterozygous pathogenic variants in *TCOF1*, rarer forms of this condition result from heterozygous pathogenic variant in *POLR1B* or *POLR1D*, or biallelic pathogenic variants in *POLR1C* or *POLR1D*.^{36,37} In 2019, Gauquelin and colleagues characterized, in a multicentre study, the clinical spectrum of 23 patients with POLR3-HLD caused by biallelic pathogenic variants in *POLR1C*. In their cohort of patients, one had craniofacial features compatible with TCS including downslanting palpebral fissures, strabismus, bitemporal narrowing, external ear anomaly, cleft palate and micrognathia corresponding to subject 28 in our cohort. Four patients had more subtle craniofacial anomalies with mild mandibular hypoplasia and one patient had laryngomalacia. Their results illustrated that POLR1C-related HLD can be associated with craniofacial features reminiscent of TCS.¹⁴ Prior *in vitro* functional studies have demonstrated that mutations in *POLR1C* associated with POLR3-HLD prevent assembly and targeting of RNA polymerase III to the nucleus

but not RNA polymerase I. In contrast, a TCS-causing mutation, p.Arg279Gln, was shown not to affect assembly of either polymerases but rather impaired targeting of RNA polymerase I to the nucleolus.⁶ This study was the first illustrating the concept that mutations in *POLR1C* coding for a subunit common to RNA polymerase I and RNA polymerase III can lead to different effects on these two protein complexes and therefore result in different or combined phenotypes. This work provided a potential pathophysiologic mechanism underlying the phenotypic heterogeneity seen with mutations in this gene.⁶ However, in a later cohort of patients described by Gauquelin and colleagues in 2019, two participants were carrying the pathogenic variant p.Arg279Gln previously associated with TCS, yet none showed abnormal craniofacial development suggesting that the underlying pathophysiologic mechanism is likely even more complex and raising the question of implications of genetic modifiers influencing the pathophysiology of POLR1C-related disorders.¹⁴

Development of craniofacial structures is a complex process occurring in an orderly fashion throughout embryonic and fetal stages. Craniofacial growth occurs due to a relatively rapid and orderly composition of mesodermal and cranial neural crest cells involved in the first and second branchial arch formation.³⁸ Interestingly, generation of insufficient neural crest cells is a known mechanism leading to general craniofacial anomalies described in *TCOF1*, *POLR1C* and *POLR1D*-related TCS.^{39,40}

Indeed, haploinsufficiency of *Tcof1* in mice and *Polr1c* or *Polr1d* in zebrafish results in deficient ribosome biogenesis, which is incapable of meeting the proliferative needs of the neuroepithelium and leads to a high degree of neuroepithelial apoptosis.^{40 41} Interestingly, the craniofacial features described here for individuals with biallelic pathogenic or likely pathogenic variants in *POLR3A* and *POLR3B* could also be potentially explained by perturbation of the neural crest cells. We hypothesize that the decrease in *POLR3A* or *POLR3B* impairs RNA polymerase III biogenesis leading to dysregulation of the expression of certain RNA polymerase III targets and thereby perturbing cytoplasmic protein synthesis essential for neural crest cell development.^{4 42} This reduced RNA and protein production may alter the proliferation of neuroepithelium and similarly lead to neuroepithelial apoptosis as seen in *Tcof1*-haploinsufficient cells in mice or *Polr1c/Polr1d*-haploinsufficient cells in zebrafish. However, further studies are required to confirm this hypothesis.

As illustrated with this study, craniofacial abnormalities are common among individuals with *POLR3*-HLD. In this cohort of patients with pathogenic or likely pathogenic biallelic variants in *POLR3A*, *POLR3B* and *POLR1C*, each patient presented at least one craniofacial abnormality. This work further expands the phenotypic spectrum of *POLR3*-HLD. We present a novel group of craniofacial features associated with *POLR3*-HLD from what has been previously described in the literature, with the exception of the TCS craniofacial features previously described in a study by Gauquelin and colleagues.¹⁴ One limitation of this study is that the description of dysmorphic features was limited by the number of pictures available for some patients. Another limitation is the small sample size. Nevertheless, sample size is quite large considering that *POLR3*-HLD is a rare condition. Moreover, parental pictures were not available to determine if some of the facial features could be familial in nature. However, the independent analysis of pictures by two physicians experienced in dysmorphology clearly established the presence of craniofacial abnormalities mainly affecting the lower face associated with pathogenic variants in genes encoding RNA polymerase III subunits.

In conclusion, with this addition to the detailed characterization of the disease phenotype, we hope for early recognition and diagnosis of individuals with *POLR3*-HLD, an important task for clinicians in an era where clinical trial development and advancement in gene therapy for rare neurodegenerative disorders has been booming. Detailed phenotyping of the condition also allows for further genotype–phenotype correlations and contribute to the advancement in understanding the pathophysiology underlying *POLR3*-HLD.

Author affiliations

¹Department of Neurology and Neurosurgery, McGill University, Montreal, Quebec, Canada

²Department of Pediatrics, McGill University, Montreal, Quebec, Canada

³Child Health and Human Development Program, Research Institute of the McGill University Health Centre, Montreal, Quebec, Canada

⁴Department of Human Genetics, McGill University, Montreal, Quebec, Canada

⁵Department of Specialized Medicine, Division of Medical Genetics, McGill University Health Center, Montreal, Quebec, Canada

⁶Department of Child Neurology, Amsterdam Leukodystrophy Center, Emma Children's Hospital, Amsterdam University Medical Centers, and Amsterdam Neuroscience, Cellular & Molecular Mechanisms, Vrije Universiteit, Amsterdam, Netherlands

⁷Division of Neurology, Children's Hospital of Philadelphia, Philadelphia, Pennsylvania, USA

⁸Department of Neurology, Perelman School of Medicine, University of Pennsylvania, Philadelphia, Pennsylvania, USA

⁹Montreal Neurological Institute, Montreal, Quebec, Canada

¹⁰Centre Mère Enfant, CHU de Québec, Québec City, Quebec, Canada

¹¹Division of Neurology, Children's Hospital of Eastern Ontario, University of Ottawa, Ottawa, Ontario, Canada

¹²Departments of Neurosciences and Pediatrics, CHU-Sainte-Justine, Université de Montréal, Montreal, Quebec, Canada

¹³Department of Pediatrics, University of California Riverside School of Medicine, Riverside Medical Clinic, Riverside, California, USA

¹⁴Centre Pluridisciplinaire de Diagnostic Prénatal, MSP Bordeaux Bagatelle, Talence, France

¹⁵Sección de Neuropediatría, Hospital Infantil Universitario Niño Jesús, Madrid, España; Grupo Clínico Vinculado al Centro de Investigación Biomédica en Red para Enfermedades Raras (CIBERER) GCV14/ER/6, Hospital Infantil Universitario Niño Jesús, Madrid, Spain

¹⁶Genomic Medicine Center, Children's Mercy Hospital, Kansas City, Missouri, USA

¹⁷University of Missouri Kansas City School of Medicine, Kansas City, Missouri, USA

¹⁸Departments of Child Health, Neurology, and Cellular & Molecular Medicine and Program in Genetics, University of Arizona College of Medicine, Phoenix, Arizona, USA

¹⁹Programs in Neuroscience and Molecular & Cellular Biology, School of Life Sciences, Arizona State University, Tempe, Arizona, USA

²⁰Pediatric Movement Disorders Program, Barrow Neurological Institute, Phoenix Children's Hospital, Phoenix, Arizona, USA

²¹Neurogenetics Unit, Department of Neurology, Hospital JM Ramos Mejia, ADC, Buenos Aires, Argentina

²²Neurogenetics Unit, Department of Neurology, Hospital JM Ramos Mejia and CONICET-Universidad Austral, Buenos Aires, Argentina

²³Centre de Référence Neurogénétique, Service de Génétique Médicale, Bordeaux University Hospital, CHU Bordeaux, Bordeaux, France

²⁴NRGEN team, INCIA, CNRS UMR 5287, University of Bordeaux, Bordeaux, France

²⁵Department of Paediatrics, Albert Szent-Györgyi Medical School, University of Szeged, Szeged, Hungary

²⁶Adult and Paediatric National Metabolic Service, Starship Children's Hospital, Auckland, Te Whatu Ora, New Zealand

²⁷Department of Medical Genetics, McGill University Health Centre, Montreal Children's Hospital, Montreal, Quebec, Canada

²⁸Department of Neurogenetics, Kennedy Krieger Institute, Johns Hopkins Medical Institutions, Baltimore, Maryland, USA

²⁹Department of Orthodontics, University of Missouri, Kansas City, Missouri, USA

³⁰Sección de Neuropediatría, Hospital Infantil Universitario Niño Jesús, Madrid, Spain

³¹Department of Laboratory Medicine, McGill University Health Centre, Montreal, Quebec, Canada

Acknowledgements The authors thank all patients for their generous cooperation with this research. The authors also thank the McGill University and Genome Quebec Innovation Centre.

Contributors AM, S-PG, IDB and GB contributed to study conception and design, acquisition, analysis and interpretation of data, drafting and critically revising the manuscript. All of the other authors contributed to acquisition, analysis and interpretation of data, drafting and critically revising the manuscript. Guarantor: GB.

Funding This study was funded by grants from the Canadian Institutes of Health Research (377869, 426534), Montreal Children's Hospital Foundation and Leuco-Action. This research was enabled in part by support provided by Compute Canada (www.computeCanada.ca). GB has received the Clinical Research Scholar Junior one award from the Fonds de Recherche du Québec – Santé (FRQS) (2012–2016), the New Investigator Salary Award from the CIHR (2017–2022) and the Clinical Research Scholar Senior award from the FRQS (2022–2025). ER is supported by a FRQS Clinical Research Scholar Senior award and is the recipient of a Canadian Research Chair CRC-II on the Neurobiology of epilepsy. We would like to thank the families for participating in our study. This work was made possible by the generous gifts to Children's Mercy Research Institute and Genomic Answers for Kids programme at Children's Mercy Kansas City

Competing interests LTT currently manages sponsored clinical trials at the site level for Ionis Pharmaceuticals (Alexander disease clinical trial 2021–present), Passage Bio (Krabbe disease and GM1 gangliosidosis clinical trials, 2021–present) and Teva Pharmaceuticals (chronic and episodic migraine clinical trials, 2022–present). He also manages a GM1 gangliosidosis natural history study sponsored by the University of Pennsylvania with funding from Passage Bio. NIW is advisor and/or co-investigator for trials in Metachromatic Leukodystrophy (Shire/Takeda, Orchard, Evidea) and other leukodystrophies (Ionis, PassageBio, Vigil Neuro, Sana Biotech), without personal payment. AV receives research grants or in-kind research support without any personal compensation from Takeda, Passage Bio, Sanofi, Affynia, Orchard Therapeutics, Eli Lilly, ISD therapeutics, Illumina, Myrtelle, Homology, Sana and Ionis. She is a site investigator for the Ionis clinical trial in Alexander's disease, SHP611 in Metachromatic leukodystrophy of Shire/Takeda and Passage Bio gene therapy in Krabbe. She serves on the scientific advisory board of the ELA foundation, the ULF Foundation and the Yaya Foundation Scientific and Clinical Advisory Council. She is a member of the Vanishing White Matter Consortium,

the H-ABC Clinical Advisory Board. She receives grant funding from this RDCRN NCATS/NINDS (U01 NS106845, U54TR002823 and R21 NS123477). GB is/was a consultant for Passage Bio Inc (2020–2022) and Ionis (2019). She is/was a site investigator for the Alexander's disease trial of Ionis (2021–present), Metachromatic leukodystrophy of Shire/Takeda (2020–2021), Krabbe and GM1 gene therapy trials of Passage Bio (2021–present), GM1 natural history study sponsored by the University of Pennsylvania with funding from Passage Bio (2021–present) and Adrenoleukodystrophy/Hematopoietic stem cell transplantation natural history study of Bluebird Bio (2019), a site sub-investigator for the MPS II gene therapy trial of Regenxbio (2021–present) and the MPS II clinical trial of Denali (2022–present). She has received an unrestricted educational grant from Takeda (2021–2022). She serves on the scientific advisory board of the Pelizaeus-Merzbacher Foundation, the Yaya Foundation Scientific and Clinical Advisory Council and is the Chair of the Medical and Scientific Advisory Board of the United Leukodystrophy Foundation. She is a member of the Vanishing White Matter Consortium, the H-ABC Clinical Advisory Board and the Chair of the POLR3-related (4H) Leukodystrophy Consortium. She is on the editorial boards of Neurology Genetics, Frontiers in Neurology – Neurogenetics and Journal of Medical Genetics.

Patient consent for publication Consent obtained from parent(s)/guardian(s)

Ethics approval This study involves human participants and was approved by Montreal Children's Hospital and McGill University Health Center Research Ethics Boards (11-105-PED, 2019-4972). Informed consent for the research study was obtained from patients and/or caregivers in addition to consent for publication of photographs.

Provenance and peer review Not commissioned; externally peer reviewed.

Data availability statement All data relevant to the study are included in the article or uploaded as supplementary information.

Supplemental material This content has been supplied by the author(s). It has not been vetted by BMJ Publishing Group Limited (BMJ) and may not have been peer-reviewed. Any opinions or recommendations discussed are solely those of the author(s) and are not endorsed by BMJ. BMJ disclaims all liability and responsibility arising from any reliance placed on the content. Where the content includes any translated material, BMJ does not warrant the accuracy and reliability of the translations (including but not limited to local regulations, clinical guidelines, terminology, drug names and drug dosages), and is not responsible for any error and/or omissions arising from translation and adaptation or otherwise.

Open access This is an open access article distributed in accordance with the Creative Commons Attribution 4.0 Unported (CC BY 4.0) license, which permits others to copy, redistribute, remix, transform and build upon this work for any purpose, provided the original work is properly cited, a link to the licence is given, and indication of whether changes were made. See: <https://creativecommons.org/licenses/by/4.0/>.

ORCID iDs

Amytice Mirchi <http://orcid.org/0000-0002-8887-1681>

Michael C Krueer <http://orcid.org/0000-0002-1373-7891>

REFERENCES

- Vanderv A, Prust M, Tonduti D, et al. Case definition and classification of leukodystrophies and leukoencephalopathies. *Mol Genet Metab* 2015;114:494–500.
- Soderholm HE, Chapin AB, Bayrak-Toydemir P, et al. Elevated leukodystrophy incidence predicted from genomics databases. *Pediatr Neurol* 2020;111:66–9.
- Gordon HB, Letsou A, Bonkowski JL. n.d. The leukodystrophies. *Semin Neurol*;34:312–20. 10.1055/s-0034-1386769 Available: <http://www.thieme-connect.de/products/ejournals/issue/10.1055/s-004-27616>
- Bernard G, Chouery E, Putorti ML, et al. Mutations of POLR3A encoding a catalytic subunit of RNA polymerase Pol III cause a recessive hypomyelinating leukodystrophy. *Am J Hum Genet* 2011;89:415–23.
- Tétreault M, Choquet K, Orcesi S, et al. Recessive mutations in POLR3B, encoding the second largest subunit of Pol III, cause a rare hypomyelinating leukodystrophy. *Am J Hum Genet* 2011;89:652–5.
- Thiffault I, Wolf NI, Forget D, et al. Recessive mutations in polr1c cause a leukodystrophy by impairing biogenesis of RNA polymerase III. *Nat Commun* 2015;6:7623.
- Dorboz I, Dumay-Odelot H, Boussaid K, et al. Mutation in POLR3K causes hypomyelinating leukodystrophy and abnormal ribosomal RNA regulation. *Neurol Genet* 2018;4:e289.
- Schmidt JL, Pizzino A, Nicholl J, et al. Estimating the relative frequency of leukodystrophies and recommendations for carrier screening in the era of next-generation sequencing. *Am J Med Genet A* 2020;182:1906–12.
- Daoud H, Tétreault M, Gibson W, et al. Mutations in POLR3A and POLR3B are a major cause of hypomyelinating leukodystrophies with or without dental abnormalities and/or hypogonadotropic hypogonadism. *J Med Genet* 2013;50:194–7.
- Wolf NI, Ffrench-Constant C, van der Knaap MS. Hypomyelinating leukodystrophies—unravelling myelin biology. *Nat Rev Neurol* 2021;17:88–103.
- Tafur L, Sadian Y, Hoffmann NA, et al. Molecular structures of transcribing RNA polymerase I. *Mol Cell* 2016;64:1135–43.
- Watt KE, Macintosh J, Bernard G, et al. RNA polymerases I and III in development and disease. *Semin Cell Dev Biol* 2023;136:49–63.
- Lata E, Choquet K, Sagliocco F, et al. RNA polymerase III subunit mutations in genetic diseases. *Front Mol Biosci* 2021;8:696438.
- Gauquelin L, Cayami FK, Sztriha L, et al. Clinical spectrum of POLR3-related leukodystrophy caused by biallelic polr1c pathogenic variants. *Neurol Genet* 2019;5:e369.
- Wolf NI, Vanderv A, van Spaendonck RML, et al. Clinical spectrum of 4H leukodystrophy caused by POLR3A and POLR3B mutations. *Neurology* 2014;83:1898–905.
- Timmons M, Tsokos M, Asab MA, et al. Peripheral and central hypomyelination with hypogonadotropic hypogonadism and hypodontia. *Neurology* 2006;67:2066–9.
- Bernard G, Vanderv A, et al. POLR3-related leukodystrophy. In: Adam MP, Mirzaa GM, Pagon RA, eds. *GeneReviews*®. Seattle (WA): University of Washington, Seattle, 1993. Available: <https://www.ncbi.nlm.nih.gov/books/NBK99167/?report=classic>
- La Piana R, Tonduti D, Gordish Dressman H, et al. Brain magnetic resonance imaging (MRI) pattern recognition in Pol III-related leukodystrophies. *J Child Neurol* 2014;29:214–20.
- Steenweg ME, Vanderv A, Blaser S, et al. Magnetic resonance imaging pattern recognition in hypomyelinating disorders. *Brain* 2010;133:2971–82.
- Perrier S, Gauquelin L, Fallet-Bianco C, et al. Expanding the phenotypic and molecular spectrum of RNA polymerase III-related leukodystrophy. *Neurol Genet* 2020;6:e425.
- Paolacci S, Li Y, Agolini E, et al. Specific combinations of biallelic POLR3A variants cause Wiedemann-Rautenstrauch syndrome. *J Med Genet* 2018;55:837–46.
- Beauregard-Lacroix E, Salian S, Kim H, et al. A variant of neonatal progeroid syndrome, or Wiedemann–Rautenstrauch syndrome, is associated with a nonsense variant in POLR3GL. *Eur J Hum Genet* 2020;28:461–8.
- Wu S-W, Li L, Feng F, et al. Whole-exome sequencing reveals POLR3B variants associated with progeria-related Wiedemann-Rautenstrauch syndrome. *Ital J Pediatr* 2021;47:160.
- Ghoumid J, Petit F, Boute-Benejean O, et al. Cerebellar hypoplasia with endosteal sclerosis is a POLR3-related disorder. *Eur J Hum Genet* 2017;25:1011–4.
- La Piana R, Cayami FK, Tran LT, et al. Diffuse hypomyelination is not obligate for POLR3-related disorders. *Neurology* 2016;86:1622–6.
- Azmanov DN, Siira SJ, Chamova T, et al. Transcriptome-wide effects of a POLR3A gene mutation in patients with an unusual phenotype of striatal involvement. *Hum Mol Genet* 2016;25:4302–14.
- Harting I, Al-Saady M, Krägeloh-Mann I, et al. Polr3A variants with striatal involvement and extrapyramidal movement disorder. *Neurogenetics* 2020;21:121–33.
- Minnerop M, Kurzwelly D, Wagner H, et al. Hypomorphic mutations in POLR3A are a frequent cause of sporadic and recessive spastic ataxia. *Brain* 2017;140:1561–78.
- Gauquelin L, Tétreault M, Thiffault I, et al. Polr3A variants in hereditary spastic paraplegia and ataxia. *Brain* 2018;141:e1.
- Di Donato I, Gallo A, Ricca I, et al. Polr3A variants in hereditary spastic paraparesis and ataxia: clinical, genetic, and neuroradiological findings in a cohort of Italian patients. *Neurol Sci* 2022;43:1071–7.
- Rydning SL, Koht J, Sheng Y, et al. Biallelic POLR3A variants confirmed as a frequent cause of hereditary ataxia and spastic paraparesis. *Brain* 2019;142:e12.
- Richards S, Aziz N, Bale S, et al. Standards and guidelines for the interpretation of sequence variants: a joint consensus recommendation of the American College of Medical Genetics and Genomics and the Association for Molecular Pathology. *Genet Med* 2015;17:405–24.
- Allanson JE, Cunniff C, Hoyme HE, et al. Elements of morphology: standard terminology for the head and face. *Am J Med Genet* 2009;149A:6–28. 10.1002/ajmg.a.32612 Available: <http://doi.wiley.com/10.1002/ajmg.a.32612>
- Perrier S, Gauquelin L, Wambach JA, et al. Distinguishing severe phenotypes associated with pathogenic variants in POLR3A. *Am J Med Genet A* 2022;188:708–12.
- Lau MCC, Kwong EML, Lai KP, et al. Pathogenesis of POLR1C-dependent type 3 Treacher Collins syndrome revealed by a zebrafish model. *Biochim Biophys Acta* 2016;1862:1147–58.
- Katsanis SH, Jabs EW, et al. Treacher Collins syndrome. In: Adam MP, Mirzaa GM, Pagon RA, eds. *GeneReviews*® [Internet]. Seattle (WA): University of Washington, Seattle; 1993–2022, 2004. Available: <https://www.ncbi.nlm.nih.gov/books/NBK1532/>
- Marszałek-Kruk BA, Wójcicki P, Dowgierd K, et al. Treacher Collins syndrome: genetics, clinical features and management. *Genes (Basel)* 2021;12:1392.
- Johnson JM, Moonis G, Green GE, et al. Syndromes of the first and second branchial arches, part 1: embryology and characteristic defects. *AJNR Am J Neuroradiol* 2011;32:14–9.
- Trainor PA, Dixon J, Dixon MJ. Treacher Collins syndrome: etiology, pathogenesis and prevention. *Eur J Hum Genet* 2009;17:275–83.
- Noack Watt KE, Achilleos A, Neben CL, et al. The roles of RNA polymerase I and III subunits polr1c and polr1d in craniofacial development and in zebrafish models of Treacher Collins syndrome. *PLoS Genet* 2016;12:e1006187.

- 41 Jones NC, Lynn ML, Gaudenz K, *et al.* Prevention of the neurocristopathy Treacher Collins syndrome through inhibition of p53 function. *Nat Med* 2008;14:125–33.
- 42 Choquet K, Forget D, Meloche E, *et al.* Leukodystrophy-associated POLR3A mutations down-regulate the RNA polymerase III transcript and important regulatory RNA BC200 *J Biol Chem* 2019;294:7445–59.
- 43 Bernard G, Thiffault I, Tetreault M, *et al.* Tremor-ataxia with central hypomyelination (TACH) leukodystrophy maps to chromosome 10q22.3-10q23.31. *Neurogenetics* 2010;11:457–64.
- 44 Al Yazidi G, Tran LT, Guerrero K, *et al.* Dystonia in RNA polymerase III-related leukodystrophy. *Mov Disord Clin Pract* 2019;6:155–9.
- 45 Pelletier F, Perrier S, Cayami FK, *et al.* Endocrine and growth abnormalities in 4H leukodystrophy caused by variants in POLR3A, POLR3B, and POLR1C. *J Clin Endocrinol Metab* 2021;106:e660–74.
- 46 Mirchi A, Pelletier F, Tran LT, *et al.* Health-related quality of life for patients with genetically determined leukoencephalopathy. *Pediatr Neurol* 2018;84:21–6.
- 47 Córdoba M, Rodríguez-Quiroga SA, Vega PA, *et al.* Whole exome sequencing in neurogenetic odysseys: an effective, cost- and time-saving diagnostic approach. *PLoS One* 2018;13:e0191228.
- 48 DeGasperi SM, Bernard G, Wolf NI, *et al.* 4H leukodystrophy: mild clinical phenotype and comorbidity with multiple sclerosis. *Neurol Genet* 2020;6:e409.

Supplemental material. Description of the craniofacial features of the 31 POLR3-HDL subjects in this study's cohort																		
Subject	Gene	High anterior hairline	High forehead	Bitemporal narrowing	Hypertelorism	Telecanthus	Long palpebral fissures	Low-set ears	Flat midface	Pinched nose	Bulbous tip of the nose	Short philtrum	Smooth philtrum	Thin upper lip	Full lower lip	Short chin	Pointed chin	Other dysmorphic features (observed in <10%)
1	POLR3A	+			+	+	+					+	+				+	Large mouth, bilateral syndactyly 2-3 toes
2	POLR3A			+	+		+		+	+				+				
3	POLR3A								+	+		+					+	
4	POLR3A				+			+									+	Chin dimple
5	POLR3A						+	+	+		+	+					+	
6	POLR3A	+	+						+	+	+					+		Sparing of lateral eyebrows
7	POLR3A	+	+		+				+			+				+		Upturned nose
8	POLR3A								+				+				+	
9	POLR3A	+	+						+				+		+			Deviating nasal root, retrognathia
10	POLR3A			+	+							+				+		Short neck
11	POLR3A	+	+							+		+					+	Triangular face
12	POLR3A								+		+		+				+	
13	POLR3A	+								+			+				+	Ptosis, bifid tip of the nose
14	POLR3A	+	+	+					+				+					Ptosis, downslanting palpebral fissure, mildly overfoled helixes, prognatism
15	POLR3A								+	+		+		+	+			Hypotelorism, broad nasal tip, low-hanging columella
16	POLR3A	+	+		+								+		+		+	Spaced medial eyebrows, broad nasal bridge
17	POLR3B	+					+		+			+	+	+	+	+		Broad and flat nasal bridge
18	POLR3B									+			+					Depressed nasal bridge, retrognathia
19	POLR3B								+	+	+		+	+		+		
20	POLR3B							+	+	+								Deviating nasal root
21	POLR3B	+				+						+	+	+	+		+	Large ears
22	POLR3B				+		+		+				+	+	+		+	Short nose
23	POLR3B	+	+			+			+						+	+		Inferior epicanthus
24	POLR3B	+	+				+		+				+	+				Hockey-stick palmar creases
25	POLR3B	+	+				+			+			+	+				Hockey-stick palmar creases
26	POLR3B		+		+			+				+	+				+	Copped ears, low hanging columella
27	POLR1C			+		+		+	+				+		+		+	Long eyelashes, long philtrum, inferior epicanthus
28	POLR1C			+	+							+						Downslanted palpebral fissure, large mouth, short neck, abnormal external ears
29	POLR1C										+	+		+			+	Peri-orbital fullness, low-hanging columella
30	POLR1C								+	+			+				+	Broad nasal bridge, retrognathia
31	POLR3A (+/- POLR3B)	+	+					+	+		+		+				+	Epicanthal fold
		14/31 (45.2%)	11/31 (35.4%)	5/31 (16.1%)	9/31 (29.0%)	4/31 (12.9%)	7/31 (22.6%)	6/31 (19.4%)	19/31 (61.3%)	11/31 (35.5%)	6/31 (22.6%)	12/31 (38.7%)	18/31 (58.0%)	9/31 (29.0%)	8/31 (25.8%)	6/31 (19.4%)	16/31 (51.6%)	
		15/31 with an anomaly of the forehead (48.4%)			16/31 with an anomaly of the eyes (51.6%)					15/31 with an anomaly of the nose (48.4%)		26/31 with an anomaly of the philtrum (83.9%)		13/31 with an anomaly of the lip (41.9%)		22/31 with an anomaly of the chin (71.0%)		