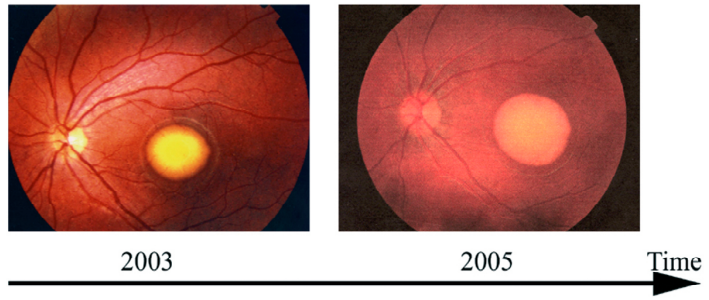

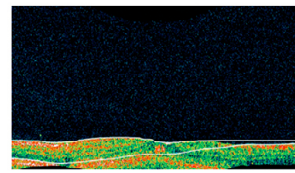
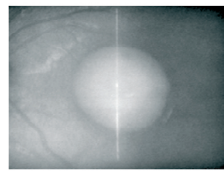
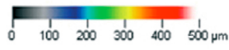


Patient IV-5

Fundus



OCT  
(2005)



Signal Strength (Max 10)	6
Foveal Thickness	183 +/- 39 microns
Total Macular Volume	6.65 mm <sup>3</sup>

